

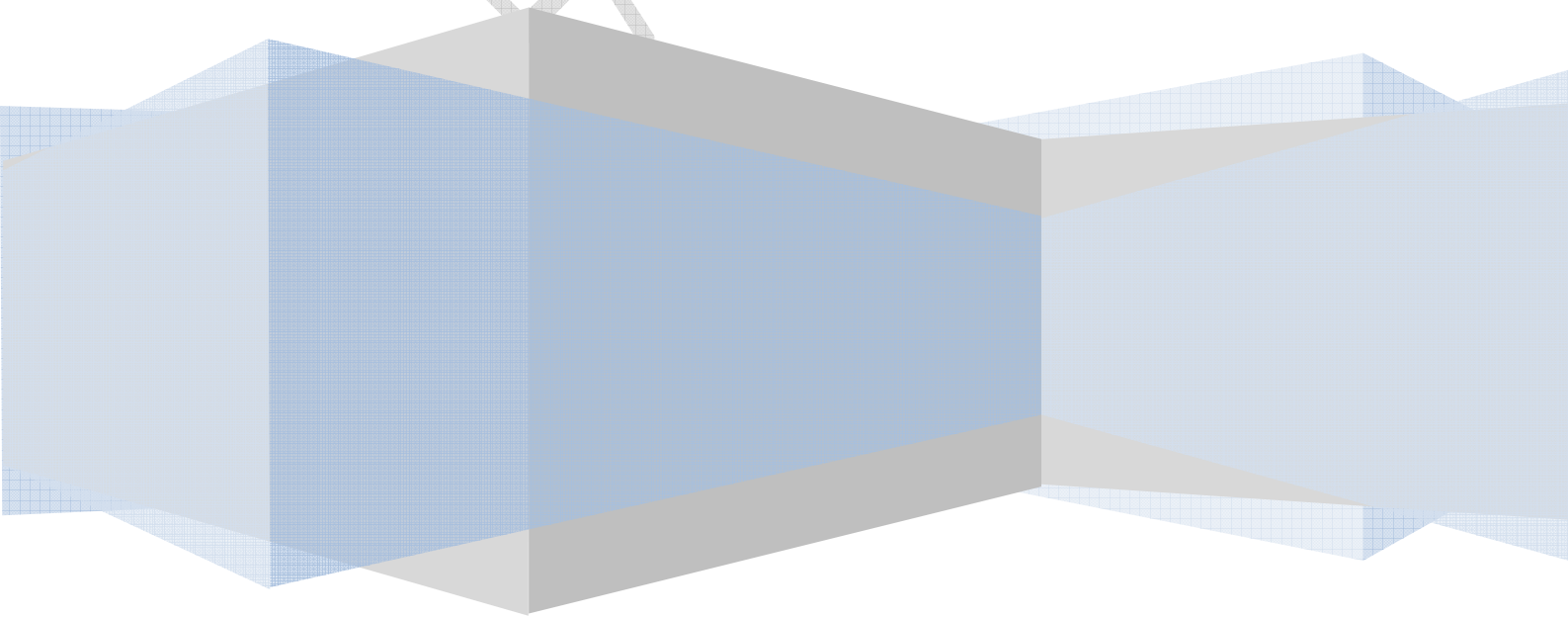
DR. FAHMI KHAN: www.fakhanqal.com

Unlimited permission is granted free of charge to print or photocopy all pages of this work for educational, not-for-profit use by faculty members, students or board candidates.

Clinical Quiz series for medical students and board candidates

Paper 6: Contains 120 best of five questions; 60 MCQs; 20 slides and answer key

Dr.fahmi khan



A: For each question below choose the single best answer

1. A 77-year-old man is admitted to the cardiac intensive care unit (ICU) following an elective triple vessel coronary artery bypass graft. On day 3 of his stay he is noted to be hypotensive and oliguric with a BP of 75/50 mmHg and a heart rate of 125 bpm (regular). Pulmonary artery catheter data show: pulmonary artery pressure 15/7 mmHg; central venous pressure of 3 mmHg; pulmonary artery occlusion pressure 5 mmHg; cardiac index $1.6\text{L}/\text{min}/\text{m}^2$ and systemic vascular resistance $2750\text{ dyne}/\text{sec}/\text{cm}^5$. **What is the most likely diagnosis?**

- A) Cardiac failure
- B) Cardiac tamponade
- C) Sepsis
- D) Hypovolemia
- E) Pulmonary embolism

2. A 75-year-old man presents with nasal regurgitation, dysphagia and hoarse voice. On examination he has a right ptosis and the pupils are unequal, the right pupil being smaller than the left. On protrusion his tongue deviates to the right and he has wasting of his right trapezius muscle. **Where is the lesion?**

- A) Right lower brainstem
- B) Right-sided sympathetic chain in the high cervical region
- C) Right jugular foramen, inside the skull
- D) Right jugular foramen, outside the skull
- E) Foramen magnum

3. You are asked to consult on a 31-year-old man with prolonged bleeding after an oral surgery procedure. He has no prior history of bleeding diathesis or family history of bleeding disorders. The patient's past medical history is remarkable for infection with the human immunodeficiency virus, with a CD4 count of $51/\text{mL}$. The examination is remarkable only for spotty lymphadenopathy. The platelet count is $230,000\text{ cells}/\mu\text{L}$. His international normalized ratio (INR) is 1.5. Activated partial thromboplastin time is 40 s. Peripheral blood smear shows no schistocytes and is otherwise unremarkable. A 1:1 mixing study corrects both conditions immediately and after a 2-h incubation. Fibrinogen level is normal. **Thrombin time is prolonged. What is the diagnosis?**

- A) Disseminated intravascular coagulation (DIC)
- B) Dysfibrinogenemia
- C) Factor V deficiency
- D) Liver disease
- E) Factor XIII deficiency

4. A 38-year-old nurse is referred with symptoms of tiredness, nausea and a change in weight. Her thyroid function tests are as follow: T3 $3.4\text{ nmol}/\text{L}$ ($0.9\text{-}2.8\text{ nmol}/\text{L}$); T4 $177\text{ nmol}/\text{L}$ ($55\text{-}144\text{ nmol}/\text{L}$); TSH $1.2\text{ mU}/\text{L}$ ($0.35\text{-}5.0\text{ mU}/\text{L}$); thyroid binding globulin (TBG) $37\text{ mg}/\text{l}$ ($12\text{-}30\text{ mg}/\text{L}$).

These results are consistent with which of the following?

- A) Autoimmune hyperthyroidism
- B) Sick euthyroid syndrome
- C) Papillary carcinoma of the thyroid
- D) Pregnancy
- E) Surreptitious thyroxin ingestion

5. A 30-year-old male patient complains of fever and sore throat for several days. The patient presents to you today with additional complaints of hoarseness, difficulty breathing, and drooling. On examination, the patient is febrile and has inspiratory stridor. **Which of the following is the best course of action?**

- A) Begin outpatient treatment with ampicillin.
- B) Culture throat for β -hemolytic streptococci.
- C) Admit to intensive care unit and obtain otolaryngology consultation.
- D) Schedule for chest x-ray.
- E) Obtain Epstein-Barr serology.

6. A 50-year-old man experienced the sudden onset of vertigo. Examination revealed dysarthria, difficulty in swallowing, a left Horner's syndrome, left palatal weakness, and loss of pain sensibility over the left face and the right limbs and trunk. He had coarse ataxia and incoordination of his left arm. The patient was alert and anxious trying to communicate with his dysarthria. He did complain of a mild occipital headache. **The cause of the responsible lesion is most likely:**

- A) Subarachnoid hemorrhage
- B) Infarction, middle cerebral artery
- C) Infarction, vertebral artery
- D) Infarction, posterior inferior cerebellar artery
- E) Pontine hemorrhage

7. A 57-year-old woman with diabetes and nephrolithiasis is admitted to the medical services for evaluation of her chest pain that began when playing with her grandchild. She had a previous myocardial infarction and is status-post a three-vessel bypass two years prior. Her medications include atenolol, lisinopril, allopurinol, and atorvastatin daily. You are called to the patient's room because the patient is currently complaining of chest pain. She reports that while talking on the telephone, she became very angry with her daughter and developed chest pain. On arrival she is lying in bed and appears uncomfortable. She is diaphoretic and appropriately anxious. Her blood pressure is 190/110 mm Hg and pulse is 110/min. She has an S4 gallop and scant bi-basilar rales. An electrocardiogram shows sinus tachycardia with a left axis deviation. Voltage criteria are met for LVH and there are ST segment depressions of 2.5mm in leads V1-V5. **The most appropriate next step in management is to**

- A) Administer verapamil, intravenously
- B) Give furosemide, intravenously
- C) Give morphine, intravenously
- D) Give nitroglycerin, intravenously
- E) Obtain a chest radiograph

8. A 74-year-old man comes to the physician for a follow-up examination. He has a 3-month history of severe pain and swelling of the metacarpophalangeal joints, wrists, elbows, and knees. Previous treatment with aspirin, methotrexate, and naproxen has not relieved his symptoms. He has one kidney. Physical examination shows no other abnormalities. His serum rheumatoid factor is increased, and serum creatinine concentration is 3.8 mg/dL. **Which of the following is the most appropriate pharmacotherapy?**

- A) Acetaminophen
- B) Colchicine
- C) Etanercept
- D) Gold salts
- E) Indomethacin

9. Which of the following families of oral agents applicable to diabetes type 2 can facilitate weight loss?

- A) Sulfonylurea agents, such as glyburide
- B) Biguanides, metformin
- C) Non-sulfonylurea secretagogues such as repaglinide
- D) Thiazolidinediones ("glitazones"), for example, pioglitazone
- E) Alpha-glucosidase inhibitors, such as acarbose

10. A 48-year-old woman is evaluated for a 4-month history of pain in the shoulders, neck, and lower back. She also has fatigue and difficulty sleeping. She does not have rash, chest pain, joint pain, anorexia, weight loss, fever, or depressed mood. On physical examination, vital signs are normal. Thyroid examination is normal. Musculoskeletal examination reveals widespread soft-tissue pain. The joints are not swollen. Muscle strength testing is limited because of pain. Deep-tendon reflexes and sensation are intact. Laboratory studies: Complete blood count Normal; Erythrocyte sedimentation rate 18 mm/h; Serum creatine kinase 164 U/L; Serum thyroid-stimulating hormone 3.0 $\mu\text{U/mL}$ (3.0 mU/L); **Which of the following is the most appropriate next step in this patient's management?**

- A) Aerobic exercise program
- B) Antinuclear antibody assay
- C) Electromyography
- D) Ibuprofen
- E) Prednisone

11. A 14-year-old boy is evaluated for short stature. He has no significant past medical history and is considered otherwise healthy by his parents. He eats a normal diet and has regular meals. His height and weight have been consistently at the 5th percentile since early childhood. His physical examination is normal, with genitalia at Tanner stage 3. **Which of the following is the most likely laboratory finding for this boy?**

- A) Bone age that is equivalent to chronologic age
- B) Decreased complement C3 level
- C) Decreased serum albumin concentration
- D) Decreased thyroid stimulating hormone
- E) Increased serum creatinine concentration

12. A 55-year-old, HIV-positive man has a fungating mass growing out of the anus. He can feel it when he wipes himself after having a bowel movement, but it is not painful. For the past 6 months, he has noticed blood on the toilet paper, and from time to time there has also been blood coating the outside of the stools. He has lost weight, and he looks emaciated and ill. On physical examination, the mass is easily visible. It measures 3.5 cm in diameter, is fixed to surrounding tissues, and appears to grow out of the anal canal. He also has rock-hard, enlarged lymph nodes on both groins, some of them as large as 2 cm in diameter. **Which of the following is the most likely diagnosis?**

- A) Adenocarcinoma of the rectum
- B) Condyloma acuminata of the anus
- C) External hemorrhoids
- D) Rectal prolapse
- E) Squamous cell carcinoma of the anus

13. A young mother complains of pain along the radial side of the wrist and the first dorsal compartment. She relates that the pain is often caused by the position of wrist flexion and simultaneous thumb extension that she assumes to carry the head of her baby. On physical examination, the pain is reproduced by asking her to hold her thumb inside her closed fist, and then forcing the wrist into ulnar deviation. **Which of the following is the most likely diagnosis?**

- A) Acute and chronic bursitis
- B) Carpal tunnel syndrome
- C) Hairline unrecognized fracture of the carpal navicular (scaphoid) bone
- D) Palmar fascial contracture (Dupuytren's contracture)
- E) Tenosynovitis of the abductor or extensor tendons of the thumb (De Quervain's tenosynovitis)

14. A 20-year-old female college student presents with a 5-day history of cough, low-grade fever (temperature 37.8°C [100°F]), sore throat, and coryza. On examination, there is mild conjunctivitis and pharyngitis. Tympanic membranes are inflamed, and one bullous lesion is seen. Chest examination shows a few basilar rales. Sputum Gram stain shows white blood cells without organisms. Laboratory findings are as follows: Hct: 31%; WBC: 12,000/μL; Lymphocytes: 50%; Mean corpuscular volume (MCV): 94 nL; Reticulocytes: 9% of red cells; CXR: bilateral patchy lower lobe infiltrates. **Which of the following is the best method for confirmation of the diagnosis?**

- A) High titers of antibody to adenovirus
- B) High titers of IgM cold agglutinins or complement fixation test
- C) Methenamine silver stain
- D) Blood culture
- E) Culture of sputum on chocolate media

15. A hypertensive woman is well controlled by amlodipine and quinapril, and she is planned for cholecystectomy. According to the American College of Cardiology/ American Heart Association (ACC/ AHA) Guidelines for Perioperative Cardiovascular Evaluation and Care for Noncardiac Surgery, **her antihypertensive medications should be**

- A) Continued during the perioperative period
- B) Held on the morning of surgery
- C) Held for 24 h before surgery
- D) Replaced by intravenous medications on day of surgery
- E) Reduced by 50% for 24 h before surgery

16. An adult patient presents with the sudden onset of massive diarrhea. Grossly, this individual's stool has the appearance of "rice-water" because of the presence of flecks of mucus. Cultures of this patient's stool grow *Vibrio cholerae*, a curved, gram-negative rod that secretes an enterotoxin consisting of a toxic A subunit and a binding B subunit. The cholera enterotoxin causes massive diarrhea by

- A) Inhibiting the conversion of Gi-GDP to Gi-GTP
- B) Inhibiting the conversion of Gs-GTP to Gs-GDP
- C) Stimulating the conversion of Gi-GDP to Gi-GTP
- D) Stimulating the conversion of Gs-GDP to Gs-GTP
- E) Stimulating the conversion of Gs-GTP to Gs-GDP

17. A 50-year-old with von Willebrand disease requires thyroidectomy. Hemostatic aids might include the following **EXCEPT**

- A) Desmopressin (DDAVP)
- B) Cryoprecipitate
- C) Aminocaproic acid
- D) Tranexamic acid
- E) Vitamin K

18. Which of the following suggests a poorer prognosis for thyroid cancer?

- A) papillary thyroid cancer with cervical node involvement
- B) Male sex
- C) age less than 30
- D) cold nodule on thyroid uptake scan
- E) high TSH concentration

19. A 60 year female presents with vague aches and pains and has a family history of osteoporosis. She is 10 years post-menopausal but has not taken any female HRT. Dual energy X-ray absorptiometry (DEXA) is requested. Which of the following values of bone mineral density measured by DEXA would signify osteopenia at a measured site?

- A) A T score of -2.6
- B) A T score of -1.8
- C) A Z score of -2.0
- D) A Z score of -1.5
- E) A T score of -0.9

20. A 60 year old female presents with recent-onset dyspnea and noisy breathing. Her chest X-ray showed right deviation of the trachea due to a retrosternal goiter. Which of the following tests is most useful in the assessment of airflow obstruction due to the goiter?

- A) Flow volume curve
- B) Forced expiratory flow volume in one second
- C) Forced vital capacity
- D) Peak expiratory flow rate
- E) Residual volume

21. A 57-year-old man was found to have an elevated total protein and monoclonal protein immunoglobulin G (IgG) kappa at 3.2 g/dL with serum free light chain (FLC) kappa/lambda ratio of 58. Diagnostic workup shows no evidence of hypercalcemia, renal insufficiency, anemia, or bone lesions (CRAB) on magnetic resonance imaging (MRI), [¹⁸F]-fluorodeoxyglucose positron emission tomography-computed tomography (FDG-PET-CT) scan. Bone marrow biopsy reveals 40% plasma cells and presence of t(4,14) on fluorescent in situ hybridization (FISH) studies. In asymptomatic patients (patients without CRAB features),

Which of the following is not considered a myeloma-defining biomarker and does not warrant initiation of treatment?

- A) Bone marrow plasma cells (BMPCs) $\geq 60\%$
- B) Involved to uninvolved serum FLC ratio ≥ 100
- C) Monoclonal protein ≥ 3.0 g/dL,
- D) >1 focal lesion on MRI studies; lesion is defined by >5 mm in size
- E) A&B

22. A 60-year-old female with a history of urinary tract infection, steroid-dependent chronic obstructive lung disease, and asthma presents with bilateral infiltrates and an eosinophil count of 15%. **The least likely diagnosis is**

- A) Bronchopulmonary aspergillosis
- B) Hypersensitivity pneumonitis
- C) Strongyloides hyperinfection syndrome
- D) Drug effect of Nitrofurantoin

23. Raynaud's syndrome can be caused by which one of the following antihypertensives?

- A) α -blockers
- B) Angiotensin-converting enzyme inhibitors
- C) β -blockers
- D) Calcium channel blockers
- E) Angiotensin receptor blockers

24. A patient on warfarin for multiple deep vein thromboses is about to undergo an emergency laparotomy for a perforated sigmoid colon. **Which of the following is the best preoperative strategy?**

- A) Discontinue warfarin therapy, administer vitamin K (2–3 mg) and check the international normalized ratio (INR) every 6–8 hours preoperatively
- B) Discontinue warfarin therapy and check the INR every 6–8 hours preoperatively
- C) Continue warfarin therapy as prescribed
- D) Discontinue warfarin therapy, administer vitamin K (2–3 mg), check the INR every 6–8 hours preoperatively, request fresh frozen plasma to cover the procedure
- E) None of the above as the surgery should be postponed

25. Which of the following is an indication for renal biopsy?

- A) Persistent hematuria in a patient with normal renal function and an otherwise negative workup.
- B) Persistent low-grade proteinuria (1–2 g/day range) with normal blood pressure and creatinine.
- C) Suspected case of IgA nephropathy.
- D) Nephrotic syndrome likely from diabetes mellitus.
- E) Persistent low-grade proteinuria with elevated blood pressure and/or elevated creatinine.

26. A 62-year-old man is awaiting an elective femoropopliteal bypass for peripheral vascular disease. He is a smoker of 60 pack years and is being treated for hypertension and hypercholesterolemia with ramipril 5 mg each morning and simvastatin 10 mg orally at night. Three weeks ago he was admitted following an ST elevation myocardial infarction. His current blood pressure is 170/110 mmHg. **Which of the following best describes the preoperative strategy?**

- A) Preoperative control of blood pressure with nifedipine is mandatory
- B) Preoperative unfractionated heparin should be started, with 4-hourly monitoring of the patient's activated partial thromboplastin time
- C) Intensive chest physiotherapy three times a day is vital postoperatively
- D) A preoperative echocardiogram is required
- E) None of the above, as the surgery should be deferred for 6 months

27. A helpful clue to differentiate diabetic ketoacidosis (DKA) from hyperosmolar nonketotic hyperglycemia (HONK) is:

- A) Serum glucose of 500 mg/dL is most consistent with the diagnosis of HONK.
- B) Fluid deficits are typically greater in DKA.
- C) Most patients who develop HONK have a prior history of complications of their IDDM.
- D) HONK most commonly presents as an acute event with illness developing over several hours, and coma is required to make the diagnosis.
- E) Focal neurologic symptoms occur more frequently in HONK.

28. Which of the following statement about Buerger disease (thromboangiitis obliterans) is FALSE?

- A) Thromboangiitis obliterans usually affects small distal arteries before affecting larger proximal arteries
- B) The disease can affect upper or lower extremities
- C) An initial manifestation of Buerger disease may be superficial thrombophlebitis
- D) Buerger disease is often associated with aortic dissection
- E) the disease can affect the cerebral arteries

29. Which One of the following blood film picture describes best advanced myelofibrosis?

- A) Hypochromic microcytic RBCs, increase platelets, and normal looking WBC
- B) Hypochromic RBCs, presence of target cells, normal platelets and normal looking WBCs
- C) Nucleated RBCs, tear drop poikilocytes, low platelets and low WBCs
- D) Macrocytosis, low platelets and low WBCs
- E) Polychromasia, spherocytes are seen, myelocytes and metamyelocytes, and normal platelets

30. Which of the following statement about intestinal tuberculosis is FALSE?

- A) It can be caused by Mycobacterium bovis.
- B) It may be clinically indistinguishable from Crohn's disease.
- C) It is often diagnosed by identification of acid fast bacilli in the stool.
- D) It commonly involves the ileocecal region.
- E) It usually responds to anti-tuberculous therapy.

31. A 62-year-old man with non-small cell lung cancer is being considered for surgical resection. Which of the following would be regarded as a contraindication to surgery?

- A) FEV₁ 1.2L
- B) Horner's syndrome
- C) Hypercalcemia
- D) Peripheral neuropathy
- E) Previous history of Myocardial Infarction

32. Regarding toxoplasmosis all of the following are true EXCEPT:

- A) Oral route is the most common mode of transmission
- B) Generalized Lymphadenopathy occur in up to 30% of pts
- C) CNS involvement is the principle manifestation of acute infection in immunocompromised patients
- D) Chorioretinitis occurs predominantly in acquired infection
- E) Spiramycin reduces transplacental transmission

33. Which one of the following is the commonest cause of death in SLE?

- A) Infection
- B) Cardiovascular disease
- C) Lupus nephritis
- D) Cerebral lupus
- E) Thromboembolism

34. A 16-year-old female patient is discovered to have a BP of 200/120 mm Hg during an episode of headache. Her preliminary work up discloses: Serum Na: 135; serum K 2.8; Serum Bicarbonate: 19; Plasma aldosterone plasma rennin activity ratio: low. Urinalysis is normal. At this stage, the best **diagnostic test** to perform is:

- A) Renal angiography
- B) 24 urine measurement of metanephrines
- C) Doppler US of the renal arteries
- D) A 24 urine measurement of the K excretion
- E) Renal scintigraphy without furosemide

35. A 48-year-old woman presents to her GP with Cushingoid facies and hyperpigmentation of the skin on her face and chest. She has smoked 20 cigarettes per day for 30 years. Examination reveals no gross abnormalities. Her chest x ray reveals a 2 cm irregularly shaped mass in the right upper lobe, in proximity to the mediastinum. A CT guided needle biopsy of the lung lesion is performed. **Which would be the most likely cytologic finding?**

- A) Adenocarcinoma
- B) Benign bronchial adenoma
- C) Bronchoalveolar cell carcinoma (BAC)
- D) Small cell (oat cell) carcinoma
- E) Squamous cell carcinoma

36. Regarding grave's disease the following are true **EXCEPT:**

- A) Ophthalmopathy may precede the onset of the hyperthyroidism.
- B) Spontaneous hypothyroidism occurs in 50% of patient.
- C) Thyrotropin receptor antibodies are founding the majority of patient
- D) Pronvltinouracil and methimazole are equally effective induction of remission of hyperthyroidism.
- E) Spontaneous remission of hyperthyroidism often occur in the trimester of pregnancy

37. A 52-year-old policeman with a history of chest tightness and dyspnea when jogging in cold weather presents to the clinic for consultation. He has lifelong nasal allergies and smoked a pack/day since a teenager, until quitting 4 years ago. He takes loratidine and multivitamins daily. His nurse practitioner used a pocket spirometer to measure his FEV1 as only 35% predicted and a lung age of 95. **What should you order next?**

- A) Methacholine test
- B) Tiotropium to treat COPD
- C) Allergen skin testing
- D) Chest CT to screen for lung cancer
- E) Repeat spirometry, pre- & post-bronchodilators

38. A 36-year-old man comes to the HIV clinic for a regular follow-up visit. He has been known to be HIV positive for three years. Antiretroviral treatment was started six months ago. His present regimen includes zidovudine, lamivudine, nelfinavir, azithromycin, and Bactrim (trimethoprim/sulfamethoxazole). He tolerates his medications well and claims to be compliant. After three months of therapy, there was a one-log reduction in his viral load, and the CD4 count increased from 45 to 285/ μ L. At the present time, his blood tests show a rise in viral load back to the initial level. There is moderate truncal obesity and facial thinning. Laboratory studies show: ALT 112 U/L, AST 98 U/L, cholesterol 240 mg/dL, and triglycerides 260 mg/dL. **What is the next step in treatment of this patient?**

- A) Continue the same medications
- B) Repeat HIV viral load in three months
- C) Genotypic analysis of a viral isolate
- D) Assess serum drug concentrations
- E) Change medications to stavudine, didanosine, and ritonavir

39. A 23-year-old healthy woman presents to your office for an annual physical examination. She has a history of a seizure disorder, which is well controlled on valproic acid. She feels well today. Two years ago, she delivered a child with meningocele during her first pregnancy. She is concerned about the recurrence of this event in a future pregnancy. Her physical examination is normal, and the urine pregnancy test is negative. **What should you tell her?**

- A) The risk of recurrence in a future pregnancy is not increased compared with the general population
- B) The risk is higher compared with the general population, but nothing can decrease it
- C) She should take folic acid 0.4 mg daily in the second trimester of pregnancy, and this will significantly decrease the risk of having her next child born with a neural-tube defect
- D) She should take folic acid 4 mg daily prior to conception and in the first several months of pregnancy
- E) All seizure medications should be ceased prior to the pregnancy

40. In restrictive lung disease due to respiratory muscle weakness, **which of the following statements is true?**

- A) Low FEV₁/FVC, high RV/TLC
- B) Low FEV₁/FVC, normal TLC
- C) Low VC, low FEV₁, normal TLC, low RV/TLC
- D) Low VC, low RV, low TLC
- E) Low VC, low TLC, high RV/TLC

41. Troponins in patients with chronic kidney disease (CKD), all are true **EXCEPT**

- A) They are used in conjunction with symptoms, electrocardiographic (ECG) changes, and cardiac imaging to diagnose acute myocardial infarction (AMI) in patients with CKD
- B) In the absence of other clinical features of ischemia, elevated troponins alone in patients with CKD may not be reliable and may be falsely positive, leading to unnecessary investigations.
- C) In many cases, troponin T is more elevated than troponin I in patients with CKD, even at baseline.
- D) Asymptomatically elevated troponin levels are associated with a worse long-term prognosis in patients with CKD.
- E) Currently, diagnostic guidelines for MI using troponins are different for patients with and without CKD.

42. A 43-year-old alcoholic man with type 1 diabetes mellitus for 21 years is admitted from the emergency department for vomiting and diabetic ketoacidosis apparently caused by missing 2 days of insulin treatment. His initial metabolic values included a pH of 7.02, a blood carbon dioxide level of 8 meq/L, a serum potassium level of 5.6 meq/L, large ketones, and a plasma glucose level of 412 mg/dL. After several hours of treatment with intravenous fluids, insulin, and potassium, the glucose level decreases to 130 mg/dL. Intravenous therapy is changed to subcutaneous twice-daily intermediate-acting insulin plus a sliding-scale short-acting insulin regimen. Eight hours later, the patient is again vomiting. His metabolic values are a pH of 7.09, large ketones, a blood carbon dioxide level of 12 meq/L, a serum potassium level of 5.2 meq/L, and a serum glucose level of 175 mg/dL. **Which of the following is not a reason for the persistent acidosis?**

- A) Alcohol withdrawal syndrome
- B) Volume expansion acidosis
- C) Premature discontinuation of intravenous insulin administration
- D) Failure to administer sodium bicarbonate
- E) Lack of absorption of subcutaneous insulin

43. CABG-related MI is defined as

- A) biomarker level elevations more than 5 times the upper reference limit plus either new pathological Q waves or new left bundle branch block (LBBB),
- B) Angiographically documented new graft or native coronary artery occlusion, or
- C) Imaging evidence of new loss of viable myocardium or new regional wall motion abnormality
- D) All of the above
- E) A&B

44. A 37-year-old woman with stigmata of chronic liver disease was admitted on the acute medical unit with fresh red hematemesis. She was adequately fluid resuscitated and received terlipressin and IV antibiotics prior to an urgent esophagogastroduodenoscopy. She had three bleeding oesophageal varices at endoscopy, and six bands were applied at multiple sites. There were no gastric varices. Post procedure she continued to have fresh hematemesis. **What is the definitive treatment of choice?**

- A) Balloon tamponade
- B) H-graft portocaval shunting
- C) Laparotomy
- D) Repeat endoscopy and radiofrequency ablation
- E) Transjugular intrahepatic portosystemic shunt (TIPSS)

45. A 40-year-old African-American man with a known seizure disorder is brought by ambulance to the emergency department. He is having a generalized tonic-clonic seizure that has lasted at least 30 minutes. On your arrival, his arms and legs are moving in a rhythmic tonic-clonic pattern. He is unresponsive to any stimuli, but has spontaneous respirations, a good pulse, and normal vital signs. He has an IV line placed by the paramedics, but has been given no medications. Blood glucose as checked by paramedics was normal. **What is the next most appropriate step in management of this patient?**

- A) Paralyze and intubate
- B) Lorazepam 0.1 mg/kg IV
- C) Phenytoin 20 mg/kg IV
- D) CT of the head
- E) EEG

46. A 60 year old woman diagnosed with giant cell arteritis was commenced on high-dose prednisolone therapy. **Which one of the following is the most appropriate treatment for the prevention of steroid-induced osteoporosis?**

- A) Bisphosphonate therapy
- B) Calcium and vitamin D
- C) Hormone replacement therapy
- D) Raloxifene
- E) Salmon calcitonin

47. Iron storage is notably elevated in each of the following conditions except for which one?

- A) Hemochromatosis
- B) Lead poisoning
- C) α -Thalassemia
- D) Sickle cell disease (SCD)
- E) Sideroblastic anemia

48. Which of the following tests is the **best indicator** of severity of Goodpasture's syndrome?

- A) Anti-GBM antibody titer
- B) ESR
- C) Decreased transfer factor
- D) Eosinophil level
- E) Increased transfer factor

49. A 45-year-old woman, who wears high-heeled, pointed shoes, complains of pain in the forefoot after prolonged standing or walking. Occasionally, she also experiences numbness, a burning sensation, and tingling in the area. Physical examination shows no obvious deformities and a very tender spot in the third inter-space, between the third and fourth toes. **There is no redness, limitation of motion, or signs of inflammation. Which of the following is the most likely diagnosis?**

- A) Gout
- B) Hallux rigidus
- C) Metatarsophalangeal articulation pain
- D) Morton's neuromas
- E) Plantar fasciitis

50. The following are common laboratory features of toxic megacolon **EXCEPT:**

- A) Metabolic alkalosis
- B) Hypokalemia
- C) Raised hematocrit
- D) Anemia
- E) Leukocytosis with left shift

51. You are reading a population study that reports 90% of people with lung cancer are smokers. Thirty percent of the people without lung cancer are also smokers. **Given this information, what is the specificity using smoking as a predictor of lung cancer?**

- A) 10%
- B) 30%
- C) 40%
- D) 70%
- E) 90%

52. A 28-year-old previously well woman is seen in the emergency room with sudden onset palpitations. The ECG shows atrial fibrillation with a ventricular rate of 140bpm. On examination she complains of a feeling of breathlessness but is able to talk in sentences. Her BP is 100/70 mmHg, SpO₂ is 99% on 6L/min oxygen. **The most appropriate first line treatment of her arrhythmia would be:**

- A) Oral digoxin 250-500 µg over 30 minutes
- B) Intravenous metoprolol 2.5-5mg over 1 minute
- C) Intravenous flecainide 100-150mg over 30 minutes
- D) Synchronized DC shock under sedation or anaesthesia
- E) Intravenous verapamil 5mg intravenous bolus

53. A 63-year-old man with a history of idiopathic pulmonary (IPF) is referred to the ICU with progressive dyspnea and type 1 respiratory failure. **Which statement is true?**

- A) Non-invasive ventilation is a useful therapeutic option
- B) Pneumonia is the commonest causes of worsening respiratory failure in patients with IPF
- C) The outlook is good for patients who survive their ICU admission
- D) An infectious cause of respiratory deterioration improves the prognosis
- E) FEV₁ is not a useful predictor of ICU survival

54. A weakness of which one of the following **would not be expected** by damage to the radial nerve in the axilla

- A) Elbow extension
- B) Elbow flexion in half supination
- C) Elbow pronation
- D) Wrist extension
- E) Finger flexion

55. Placement of vena cava filter should be considered in the following cases **EXCEPT:**

- A) A patient requiring urgent major vascular surgery who was diagnosed with a proximal deep vein thrombosis 1 week previously
- B) A patient with malignancy who develops a pulmonary embolism despite maximal therapeutic anticoagulation (INR= 3.5)
- C) A patient with a recent intracerebral hemorrhage who develops a proximal deep vein thrombosis
- D) A pregnant patient who develops a pulmonary embolism 2 weeks before her expected date of delivery
- E) A patient newly diagnosed with the antiphospholipid syndrome

A 49-year-old female with a 5-year history of diabetes mellitus type 2, presents for an initial visit. She has no known complications of diabetes. She takes metformin, glyburide, and aspirin. On examination, you find a pleasant, obese female in no distress. Her blood pressure is 136/86 mm Hg, pulse 86, respirations 14, and temperature 37°C . As you discuss monitoring her diabetes, you recommend screening for early kidney disease.

56. Which of the following approaches is the recommended way to screen for diabetic kidney disease?

- A) Obtain a 24-hour urine collection for albumin now and again in 3 years.
- B) Obtain a spot urine microalbumin every year.
- C) Obtain a spot urine microalbumin/creatinine ratio every year.
- D) Obtain a urinalysis every year.
- E) Obtain a serum creatinine every year.

57. Her microalbumin/creatinine ratio is 42 mg/g. The next step to confirm microalbuminuria is:

- A) Repeat urine microalbumin/creatinine ratio.
- B) Urine dipstick for protein.
- C) 24-hour urine collection for total protein excretion.
- D) Serum creatinine
- E) Start ACE inhibitors

58. Which of the following can cause a false-negative microalbumin/creatinine ratio?

- A) Vigorous exercise.
- B) Fever.
- C) Cachexia.
- D) Poor glycemic control.
- E) Large muscle mass

59. The evaluation in a newly diagnosed case of acute lymphoid leukemia (ALL) should routinely include all of the following EXCEPT:

- A) bone marrow biopsy
- B) cell-surface phenotyping
- C) cytogenetic testing
- D) lumbar puncture
- E) plasma viscosity

60. A 20-year-old man who has been abusing inhalants for many years was admitted with sudden collapse. The ambulance crew said he was inhaling solvent by rebreathing from a plastic bag. He is transferred to the ICU. A few minutes later he stops breathing and the cardiac monitor records ventricular fibrillation rhythm. In resuscitating this patient, which of the following should be avoided?

- A) Direct current shock
- B) Intubation
- C) Oxygen therapy
- D) Intravenous β -blockers
- E) Intravenous adrenaline

61. A 51-year-old woman undergoes a successful bone marrow transplant from a matched unrelated donor for refractory Hodgkin's disease. She is discharged from the hospital on no medications and is feeling well. At an appointment 6 months posttransplant, she is well with no evidence of malignancy. Three weeks later, she travels to Florida with her family. She is cautious of the sun but develops sunburn on her face, despite wearing sunscreen and a protective hat. When she returns from her trip 5 days later, she presents with persistent erythema of her face. She also states that her wrists and hands have been sore for the past 2–3 weeks. On examination, her face is mildly tender to touch, and a rash is present. Her hands are diffusely swollen. She is afebrile, and the remainder of her physical examination is benign.

What is the most likely diagnosis?

- A) Graft-versus-host disease
- B) Hypersensitivity to sunlight due to the patient's antirejection regimen
- C) New-onset systemic lupus erythematosus
- D) Rosacea
- E) Staphylococcal skin infection acquired during travel

62. A 50-year-old woman with diabetes mellitus presents with backache and inability to walk unaided. This came on suddenly, while she was trying to lift her shopping bag from the car boot.

Which of the following is most suggestive of a lesion of the sciatic nerve?

- A) Absent knee tendon jerk
- B) Foot drop
- C) Inability to flex the hip
- D) Decreased sensation on the anterior thigh and medial leg
- E) Intervertebral disc prolapse at L2/L3 level

63. A 68-year-old woman has been receiving mechanical ventilation for 10 days for community-acquired pneumonia. You are attempting to decide whether the patient is appropriate for a spontaneous breathing trial. **Which of the following factors would indicate that the patient is not likely to be successfully extubated?**

- A) Alert mental status
- B) Positive end-expiratory pressure (PEEP) of 5 cmH₂O
- C) pH >7.35
- D) Rapid shallow breathing index (respiratory rate/tidal volume) >105
- E) SaO₂ >90% on FIO₂ <0.5

64. A 60-year-old man attends clinic because of hypertension. His BP in clinic is 170/90 mmHg and his echocardiogram shows mild LVH and mild LA dilatation. He is not diabetic and has no other medical history of note. **Which one of the following medications is most effective in preventing AF?**

- A) ACE inhibitors
- B) Beta-blockers
- C) Calcium-channel antagonists
- D) Diuretics
- E) Alpha-blockers

65. Each of the following is a potential side effect of weekly low-dose (5-15 mg) methotrexate used to treat rheumatoid arthritis **EXCEPT:**

- A) Leukopenia
- B) Alopecia
- C) Nephropathy
- D) Stomatitis
- E) Thrombocytopenia

66. A 45-year-old man is evaluated in the clinic for asthma. His symptoms began 2 years ago and are characterized by an episodic cough and wheezing that responded initially to inhaled bronchodilators and inhaled corticosteroids but now require nearly constant prednisone tapers. He notes that the symptoms are worst on weekdays, but he cannot pinpoint specific triggers. His medications are an albuterol metered-dose inhaler (MDI), a fluticasone MDI, and prednisone (10 mg/d PO). The patient has no habits and works as a textile worker. Physical examination is notable for mild diffuse polyphonic expiratory wheezing but no other abnormality. **Which of the following is the most appropriate next step?**

- A) Exercise physiology testing
- B) Measurement of forced expiratory volume in 1 s (FEV₁) before and after work
- C) Methacholine challenge testing
- D) Skin testing for allergies
- E) Sputum culture for *Aspergillus fumigatus*

A 28-year-old American marine presents with fever, red eyes, backache and swelling and pain in his right knee and left ankle following a trip to Thailand. His mother had psoriasis and an aunt diabetes mellitus. On examination he is febrile, and there is warmth, swelling and tenderness of the right knee and left ankle. There are mouth ulcers, nail pitting and a rash on his soles, and conjunctivitis.

67. Which of the following is your first investigation?

- A) Joint aspiration
- B) Rheumatoid factor
- C) Serum urate
- D) Measurement of inflammatory markers
- E) Urethral smear

68. What is the diagnosis?

- A) Gonococcal arthritis
- B) Psoriatic arthritis
- C) Non-gonococcal septic arthritis
- D) Reiter's syndrome
- E) Osteomyelitis

69. A 40-year-old female who is intubated and ventilated following a subarachnoid hemorrhage (SAH) 7 days previously has a serum sodium concentration of 128mmol/l and serum osmolality of 270 mOsm/kg. **Which of the following statements is true?**

- A) Cerebral salt-wasting syndrome (CSWS) is rarely associated with SAH
- B) Cerebral salt-wasting syndrome is associated with a reduced serum osmolality
- C) To diagnose SIADH, the patient must be clinically dehydrated
- D) SIADH almost always requires pharmacological treatment
- E) To diagnose SIADH urine osmolality must be greater than serum osmolality

70. A 19-year-old female presents to the emergency department stating that she took an overdose of 50 x 500 milligram paracetamol tablets 30 minutes ago. It is decided to attempt gastrointestinal decontamination. **Which of the following regimens would be the most appropriate in order to reduce paracetamol absorption in this patient?**

- A) 30 milliliters of ipecacuanha administered by mouth to induce vomiting
- B) Whole bowel irrigation with 1.5 liters/hour polyethylene glycol via nasogastric tube until the effluent runs clear
- C) Whole bowel irrigation with 2 liters/hour polyethylene glycol via nasogastric tube until the effluent runs clear
- D) Gastric lavage via a 30 F orogastric tube
- E) Activated charcoal 50 grams administered by mouth

71. A 55-year-old man is brought to the emergency department by his family. They state that he has been vomiting large amounts of bright red blood. The patient is an alcoholic with cirrhotic liver disease and a history of portal hypertension and esophageal varices. His vitals on arrival are HR 110 beats per minute, BP 80/55 mm Hg, RR 22 breaths per minute, and temperature 99°F. The patient appears pale and is in moderate distress. **Which of the following is an inappropriate option in the initial management of a hypotensive patient with a history of known esophageal varices presenting with hematemesis?**

- A) Sengstaken-Blakemore tube placement
- B) Two large-bore IV lines and volume repletion with crystalloid solutions
- C) Nasogastric (NG) lavage
- D) IV octreotide
- E) Gastrointestinal (GI) consult

72. A 59-year-old man presents with a 6.8-kg (15-lb) unintentional weight loss over 2 months, with occasional night sweats. He notices some abdominal fullness but no pain, and his last colonoscopy was negative for polyps. He has never smoked tobacco, but he has had prior radiation exposure as an x-ray technician. Physical examination is significant for splenomegaly, with no signs of jaundice. Fecal occult blood is negative. X-ray of the chest is clear. A complete blood count shows a WBC count of 126,000/mm³, and a peripheral smear shows a leukocytosis with all stages of maturation seen and 3% blasts. **Which of the following tests would confirm the diagnosis?**

- A) Bone marrow biopsy with hypercellularity and elevated proportion of blasts
- B) Cytogenetic identification of t(9;22)
- C) Elevated α -fetoprotein
- D) Lymph node biopsy showing Reed-Sternberg cells
- E) Repeat colonoscopy showing colonic polyps

73. A 34-year-old African-American diabetic man is brought to the ED after collapsing on the bus on his way home from work. His blood sugar was 20 mg/dL on admission. After resuscitative measures, his blood sugar is 90 mg/dL; he is awake, alert, oriented, and appears stable. His insulin dosage had recently been adjusted, and physical examination reveals white patches in his mouth. A contrast-enhanced CT study done in the ED is normal. **Which of the following is the most appropriate step to manage his condition and prevent morbidity?**

- A) Administer amphotericin B
- B) Administer glucose
- C) Administer mannitol
- D) Do nothing; this represents normal oral flora
- E) Manage blood sugars and insulin medication

74. Which one of the following is associated with treatment of COPD with inhaled corticosteroids?

- A) An increased risk of monilial vaginitis
- B) An increased risk of bruising
- C) Consistent improvement in FEV₁
- D) A decreased risk of pneumonia
- E) Decreased mortality

75. Patients being treated with amiodarone should be monitored periodically with serum levels of

- A) Cortisol
- B) Creatine phosphokinase
- C) Creatinine
- D) LDH
- E) TSH

A 15-year-old asymptomatic girl is found to have an enlarged thyroid. She states that the front of her neck has been growing slowly for more than a year.

76. The most likely diagnosis is

- A) Iodine deficiency
- B) Congenital hypothyroidism
- C) Graves' disease
- D) Exogenous ingestion of synthroid
- E) Lymphocytic (Hashimoto's) thyroiditis

77. Treatment for this patient includes

- A) Iodine
- B) Synthroid if she becomes symptomatic
- C) Propylthiouracil (PTU)
- D) Psychiatry consult
- E) Surgical removal of thyroid

78. A 45-year-old woman with Crohn's disease and a small intestinal fistula develops tetany during the second week of parenteral nutrition. The laboratory findings include Ca 8.2 meq/L; Na 135 meq/L; K 3.2 meq/L; Cl 103 meq/L; PO₄ 2.4 meq/L; albumin 2.4; pH 7.48; 38 kPa; P 84 kPa; bicarbonate 25 meq/L. **The most likely cause of the tetany is**

- A) Hyperventilation
- B) Hypocalcemia
- C) Hypomagnesemia
- D) Essential fatty acid deficiency
- E) Focal seizure

79. You are treating a pregnant woman for preeclampsia while awaiting emergent delivery. She shows signs of iatrogenic hypermagnesemia. After infusing isotonic saline and giving a loop diuretic, **you can reverse her respiratory depression and hypotension by giving:**

- A) 20 mL of 10% calcium chloride IV bolus
- B) 25 mL of intravenous potassium phosphate
- C) 40 mEq potassium chloride intravenously over 2 hours
- D) 50–100 mEq IV sodium bicarbonate
- E) Intravenous methotrexate

80. In evaluating patients with alcoholic ketoacidosis (AKA) it is important to remember that:

- A) Serum glucose is usually elevated, making differentiation from DKA difficult.
- B) If serum and urine ketones are low and the anion gap is elevated in an alcoholic with a history of decreased food intake and vomiting, lactic acidosis is more likely than diabetic ketoacidosis.
- C) Patients with DKA are likely to have a low serum bicarbonate, in contrast to the near-normal or elevated levels of bicarbonate seen in patients with AKA.
- D) Glycosuria is a common finding in both DKA and AKA.
- E) Treatment of patients with AKA includes isotonic saline, glucose, and low-dose insulin therapy, and serial estimations of serum or urine ketones.

81. A 16-year-old boy is admitted to the hospital for pneumonia. The patient reports that over the past 3 days he has had an increasing cough, productive of thick, green sputum and pleuritic chest pain. He has a history of cystic fibrosis and has been hospitalized for pneumonia 9 times in the past 3 years. He has never been intubated, but has required prolonged hospital stays at times in order to manage his infections. His medications include pancreatic enzymes and acetylcysteine nebulizers. **The most appropriate management of this patient is to**

- A) Begin aggressive chest physiotherapy
- B) Give him inhaled beta agonists
- C) Enroll him in gene therapy trials
- D) Evaluate him for lung transplantation
- E) Obtain a sputum culture and await results for directed antibiotic therapy

82. A 55-year-old man presents with sudden onset of severe headache, which he likens to a 'hammer blow' to the back of the head. A gadolinium-enhanced MRI shows a hemorrhagic lesion in the anterior cranial fossa. **Which one of the following vessels is involved?**

- A) Anterior communicating artery
- B) Basilar artery
- C) Internal carotid artery
- D) Middle cerebral artery
- E) Posterior communicating artery

83. Which of the following statements is true regarding non-ST elevation acute coronary syndromes (NSTEMI) compared with ST elevation myocardial infarctions (STEMI)?

- A) Initial mortality of NSTEMI is higher
- B) Six-month mortality of STEMI is higher
- C) Long-term mortality of NSTEMI is higher
- D) STEMI patients are older with more comorbidity
- E) STEMI is more frequent

84. A patient notices that whenever he has an upper respiratory infection or gastroenteritis, that there is blood in his urine. He states that even when he has been well that when his urine has been dipped there is still a trace of blood. He is found to be hypertensive. Given the most likely diagnosis, **what antihypertensive is the treatment of choice?**

- A) Ramipril
- B) Losartan
- C) Atenolol
- D) Amlodipine
- E) Bendroflumethiazide

85. An 18-year-old man who has been in good health underwent a routine physical examination was found to have 2+ proteins on a dipstick urinalysis. The urine sediment was normal and urine PH 5. The patient has no other abnormal physical or laboratory findings. The urine collection demonstrated 800mg protein and the creatinine clearance was normal. Which of the following procedures is most appropriate?

- A) Urine protein electrophoresis
- B) Renal biopsy
- C) Measurement of protein excretion in supine and upright position
- D) Re-evaluation in 1 year
- E) Intravenous pyelography

86. A 61-year-old with a history of a myocardial infarction 2 years ago with a known ejection fraction of 25% presents to A&E with a 2 hour history of mild palpitations. He is otherwise fit and well. His ECG monitoring shows a regular broad complex tachycardia at a rate of 170 bpm which self-terminated before a 12-lead ECG was performed. His U&Es are normal. The patient's blood pressure was 130/90 mmHg during the tachycardia and he was not unduly distressed. He is transferred to CCU where a 12-lead ECG shows LBBB with QRS duration of 100 ms.

- A) He needs an implantable cardioverter defibrillator (ICD)
- B) He needs an urgent revascularization
- C) He needs an EP study
- D) He tolerated his tachycardia well; therefore it is likely to be an SVT with aberrancy
- E) He should be commenced on flecainide

87. Five post office workers have all come down with a similar respiratory illness characterized by low-grade fever, chills, cough, dyspnea on exertion, and generalized malaise. A chest radiograph taken on one of them shows mediastinal edema and sputum Gram stain shows WBCs and large Gram-positive rods. A blood culture also shows Gram-positive rods. **This infection was most likely acquired by:**

- A) Inhalation of vegetative bacteria
- B) Inhalation of conidia
- C) Inhalation of spores
- D) Traumatic inoculation of vegetative bacteria
- E) Traumatic inoculation of spores

88. A 31-year-old man with a known history of alcoholic liver disease is reviewed following a suspected esophageal variceal hemorrhage. He has been resuscitated and intravenous terlipressin has been given. His blood pressure is now 104/60 mmHg and his pulse is 84/min.

What is the most appropriate intervention?

- A) Transjugular Intrahepatic Portosystemic Shunt
- B) Surgical referral
- C) Endoscopic variceal band ligation
- D) Sengstaken-Blakemore tube
- E) Endoscopic sclerotherapy

89. Carcinoid tumours of the foregut may be associated with which of the following

- A) Cushing's syndrome
- B) hypercalcemia
- C) pellagra
- D) pulmonary hypertension
- E) carcinoid syndrome

90. A 42-year-old woman who smokes tobacco is found to have acute-onset respiratory distress and tachycardia 4 hours after a non-emergent cholecystectomy. She is subsequently treated for a symptomatic pulmonary embolism. She is begun on low-molecular-weight heparin and warfarin while in the hospital and is supplied with subcutaneous doses of low-molecular weight heparin to take at home for a total course of 5 days, in addition to the warfarin that she will take for at least 6 months. The initial 5 days of overlap of both heparin and warfarin is necessary because at the beginning of treatment, warfarin actually leads to hypercoagulability. **What is the underlying reason for this?**

- A) There is an initial increase in vitamin K–dependent coagulation factors
- B) Venous valvular insufficiency is exacerbated during the first 3 days of warfarin therapy
- C) Warfarin causes a more rapid drop in the levels of proteins C and S than factors II, VII, IX, and X
- D) Warfarin induces resistance of factor V to degradation by activated protein C
- E) Warfarin leads to an initial increase in platelet aggregation

91. A 45-year-old female with prolonged history of Raynaud's phenomenon and arthralgia, came to you because of cough and exertional Dyspnea of few months duration. **The following test will help you determine her response to treatment:**

- A) Chest X-Ray
- B) CT scan of the chest
- C) CO diffusion capacity
- D) Capillaryscopy
- E) Leukocyte count of Bronchoalveolar lavage

92. Initially, screening tests for hepatitis C infection include enzyme immunoassay (EIA). If the EIA is positive, recombinant immunoblot assay or polymerase chain reaction may be used for confirmation of results. To minimize the chance that persons who are not infected with hepatitis C test positive, **which of the following is the most important?**

- A) The EIA must have a high positive predictive value
- B) The EIA must have high sensitivity
- C) The EIA must have high specificity
- D) The recombinant immunoblot assay or polymerase chain reaction must have high sensitivity
- E) The recombinant immunoblot assay or polymerase chain reaction must have high specificity

93. A 61-year-old female is brought to the emergency department with acute right hemiparesis and aphasia one hour prior to presentation. She has a history of poorly controlled diabetes mellitus and hyperlipidemia and no known history of hypertension or peptic ulcer disease. On examination there is dense right hemiplegia and global aphasia. BP is 230/120 mmHg and heart rate is regular. CT scan brain shows no bleeding 2hrs after symptoms. CBC, PT and electrolytes were normal. **Her best management now is:**

- A) TPA (tissue plasminogen activator) with hope to open closed the middle cerebral artery.
- B) IV antihypertensive and transfer to ICU
- C) Intubation and hyperventilation to counteract brain oedema.
- D) If carotid echocardiogram shows significant left side stenosis (such as 90% stenosis), she needs emergency vascular consult for carotid endarterectomy
- E) Oral antihypertensives and keep him in the ward

94. A 40-year-old patient has family history of Autosomal dominant polycystic kidney disease. She is asymptomatic but she is worry about her teenager and likes to screen her for the polycystic disease. **At this time you should:**

- A) Reassure the mother and explain that her daughter cannot have the disease
- B) Order a renal ultrasound for the daughter.
- C) Order renal CT scan for the daughter.
- D) Screen the mother for polycystic renal disease by renal ultrasound.
- E) Proceed with chromosomal studies for the daughter.

95. During a routine examination, a 55-year-old man, nonsmoker, is found to have a 1.5 cm uncalcified nodule in right upper lobe. He has no respiratory symptoms. No earlier chest radiographs are available for comparison. There is no past history of malignancy or other systemic disorders. **Which of the following is the best recommendation for this patient?**

- A) Extensive testing to detect nonpulmonary malignancy
- B) Thoracoscopic resection
- C) Bronchoscopic brush and biopsy
- D) needle aspiration under CT guidance
- E) Repeat chest radiography in 3 month

96. A 60-year-old man during pilgrimage days complained of malaise tiredness and headache. While he was being examined by the duty doctor he collapsed. On arrival to the hospital he was in coma. His son gave history that his father was taking propranolol in the last 2 years. On examination his rectal temperature was 42° C. The following are additional features of the underlying disease **EXCEPT:**

- A) Serum Calcium of 12.5 mg/dl (3.125 mmol/L)
- B) Disseminated intravascular coagulopathy (DIC)
- C) Lactic acidosis

- D) Acute tubular necrosis (ATN)
- E) Elevated liver enzymes

97. All of the following statements regarding non-alcoholic steatohepatitis (NASH) are correct **EXCEPT:**

- A) Liver biopsy is the only means of accurately diagnosing NASH.
- B) Weight loss has been shown to result in improvement of elevated liver enzymes.
- C) Patients with NASH can develop liver cirrhosis.
- D) Histologically it is characterized by severe portal or peri-portal inflammation.
- E) Laboratory studies cannot identify patients at risk of progression.

98. A new blood test for *Plasmodium falciparum* is developed. Initial screening indicates that the test is much more sensitive for the parasite, and is just as specific. **What effect would a switch to the new test have in screening a certain population for *Plasmodium* infection?**

- A) A lower false-negative ratio and a higher negative predictive value
- B) A lower false-negative ratio and a lower positive predictive value
- C) A lower false-positive ratio and a higher positive predictive value
- D) A lower false-positive ratio and a lower negative predictive value
- E) The effect on positive predictive value and negative predictive value cannot be known without knowledge of the disease prevalence

99. A 17-year-old girl presents to the obstetrics and gynecology clinic with her mother. The mother says that she became concerned about a year ago because her daughter had not yet menstruated and she did not have significant breast development. There is no significant family history, except for some cousins who are color blind. With the mother out of the examination room, the patient denies ethanol, tobacco, and illicit drug use and sexual activity. Physical examination reveals a normal-appearing girl in no acute distress with minimal breast development and a lack of pubic hair. She is 168 cm (5 ft 6 in) tall, and weighs 61.2 kg (135 lb). Cardiac examination reveals no murmurs, rubs, or gallops, with point of maximal impulse at the right midclavicular line between the third and fourth intercostal space. Gynecologic examination reveals a vagina without rugae and a cervix that is easily visualized. There is no discharge. Laboratory results reveal a negative pregnancy test. **What is the most likely diagnosis in this patient?**

- A) Androgen insensitivity syndrome
- B) Gonadal dysgenesis
- C) Kallmann's syndrome
- D) Kartagener's syndrome
- E) Pregnancy

100. On your ward round you review a patient who is 48 hours post anterior STEMI treated successfully with primary angioplasty. He has type 2 diabetes and hypertension. He is gradually improving, having initially suffered with heart failure. He still feels 'chesty' and auscultation reveals minimal basal crepitations. Echocardiography has revealed an ejection fraction of 40%. Blood pressure is 110/70 mmHg with heart rate 55 bpm at rest. Ramipril has been titrated to 2.5 mg twice daily with bisoprolol 2.5mg/daily. U&Es have remained normal. **How would you improve his medical treatment?**

- A) Add furosemide 40 mg/daily
- B) Reduce the bisoprolol
- C) Further titrate the ramipril
- D) Add Eplerenone 25 mg/daily
- E) Add isosorbide mononitrate MR 30 mg/daily

101. Features of type 1 renal tubular acidosis include all of the following **EXCEPT**:

- A) Normal AG acidosis
- B) Hypokalemia
- C) Ca phosphate stone formation
- D) Urine pH decrease below 4, following oral ammonium chloride loading test
- E) Raised serum PTH hormone

102. Regarding *Listeria monocytogenes* infection all the following statements are true **EXCEPT**:

- A) Food borne transmission is the most common cause of epidemics
- B) Pregnancy associated infection result in increased risk of abortion and stillbirth
- C) Meningitis is the most common presentation of CNS infection
- D) Measurement of antibodies to listeriolysin O is the most sensitive diagnostic test
- E) Combination of ampicillin and gentamycin is the treatment of choice

103. In Bird's Fancier disease the following features are true **EXCEPT**:

- A) Respiratory failure type 1
- B) Normal FEV1/FVC
- C) Wheezy chest
- D) Dyspnea usually occur 4-6 hrs after exposure to antigen
- E) Normal esinophil

104. A 60-years-old man is brought to the ER following a grand mal seizure. He has a 10 days history of headache, fever, aphasia, right hemi-paresis and confusion. An EEG shows left temporal slowing with epileptic discharges. After MRI brain, CSF reveals 100 lymphocytes, 350 RBC, protein of 90 and normal glucose. Which of the following is the **MOST likely** diagnosis?

- A) Subarachnoid hemorrhage
- B) Bacterial meningitis
- C) Tuberculous meningitis
- D) Herpes simplex encephalitis
- E) Cryptococcal meningitis

105. A 26-years-old man was told to have recurrent sinusitis, presented with cough, sputum production, and SOB on exertion of the last five years. Physical exam of chest was normal. CXR is normal. **The next diagnostic test is:**

- A) High resolution CT
- B) Bronchogram
- C) Sputum collection for bacteriology
- D) Bronchoscopy
- E) CT scan of the sinuses

106. A 45-year-old man has been taking Levothyroxine 0.15 mg/day, for 15 years for treatment of hypothyroidism. At his annual check-up, you obtain the following test results: serum T4 9.2ug/dL (118 nmol/L), (N 60-150), TSH 16 uU/ml (0.5-5.0). His serum TSH was normal last year and he took the same preparation of Levothyroxine and no other medications. **The best interpretation of the data is that the patient:**

- A) Has now developed a pituitary tumor
- B) Has pituitary resistance to thyroid hormone
- C) Interrupted his treatment and then resumed it before the checkup
- D) Is taking an ineffective generic preparation of Levothyroxine
- E) Has developed malabsorption

107. A 65-year-old male with severe dilated cardiomyopathy due to chronic ethanol use. His BP is 100/70; HR is 110, and increased JVP, bilateral basal crepitations and 2+ lower limbs edema. **Which of the following would be the most appropriate to improve his long term prognosis?**

- A) Digoxin
- B) Furosemide
- C) Amlodipine
- D) Spironolactone
- E) Amiodarone

108. A small college has adopted an aggressive immunization policy which includes use of the newest Hib, meningococcal, and pneumococcal vaccines. Despite this an outbreak of meningitis has developed on campus with clear evidence of transmission between roommates. **Which of the following would have the greatest potential to produce an outbreak under these circumstances?**

- A) Haemophilus influenzae, type b
- B) Haemophilus influenzae, type a
- C) Neisseria meningitidis, group A
- D) Neisseria meningitidis, group B
- E) Streptococcus pneumoniae, type 24

109. A 28-year-old man undergoes an endoscopic transthoracic sympathectomy for palmar hyperhidrosis. Postoperatively, he has developed ptosis of his eye. **This is due to iatrogenic damage to which one of the following nerves?**

- A) 8th cervical nerve
- B) 1st thoracic nerve
- C) Lower cord of brachial plexus
- D) 2nd thoracic ganglion
- E) 7th cervical nerve

110. In the diagnosis of Cushing syndrome; **having a high ACTH level with unsuppressed cortisol level after dexamethasone 1 mg suppression test means:**

- A) The patient has pituitary adenoma
- B) The patient needs more workup
- C) The patient has carcinoid syndrome
- D) The patient has iatrogenic Cushing syndrome
- E) The patient has adrenal tumor

111. A 72-year-old man presented with a 3-week history of dysphagia and was found to have a large oesophageal adenocarcinoma at 37 cm. **Which of the following is the most significant predisposing factor in the pathogenesis of esophageal adenocarcinoma?**

- A) Alcohol excess
- B) *Helicobacter pylori* infection
- C) Obesity
- D) Smoking
- E) Social deprivation

112. A 28-year-old man with no significant medical history presents with shortness of breath and pleuritic chest pain acute in onset 4 hours ago. He arrived in Phoenix from Boston 1 day ago by plane. The patient's father has a history of recurrent DVT. On physical examination he is tachypneic, tachycardic, and oxygen saturation is 88% on room air. Pulmonary examination

reveals no focal crackles, wheezes, or other abnormalities. ABG analysis shows a respiratory alkalosis with hypoxemia. The patient is admitted and an evaluation for hypercoagulable state is begun. **The most likely underlying disorder in this patient would be:**

- A) Factor V Leiden defect
- B) Antithrombin deficiency
- C) Antiphospholipid syndrome
- D) Malignancy
- E) Protein C deficiency

113. Which of the following statements regarding AIDS is true?

- A) Oral hairy leukoplakia is caused by an underlying squamous cell carcinoma
- B) AIDS is the most likely diagnosis if *mycobacterium avium intracellulare*(MAI) is isolated from a biopsy specimen of an enlarged lymph node in an otherwise healthy individual presenting with generalized lymphadenopathy
- C) Sputum culture is likely to provide diagnostic results for *Pneumocystis jiroveci*
- D) Herpes simplex virus (HSV) infection is the most common cause of retinitis in AIDS
- E) Kaposi's sarcoma is encountered equally among homosexual and heterosexual AIDS patients

114. Which of the following features is most characteristic of Waldenstrom macroglobulinemia?

- A) Bone pain
- B) Monoclonal Ig M peak
- C) Renal impairment
- D) Multiple osteolytic lesions
- E) Absence of immune paresis

115. A 45-year-old woman is planning a 2-week trip to Kenya. Her itinerary includes overnight stays in several game parks. She has mild osteoarthritis, no known allergies, and takes no prescription medications. She seeks your advice regarding prevention of malaria. **Which of the following is indicated for prophylaxis of malaria in this patient?**

- A) Chloroquine
- B) Quinine
- C) Atovaquone/proguanil
- D) Metronidazole
- E) Trimethoprim/sulfamethoxazole

116. A 31-year-old with lupus nephritis presents to your office following a renal biopsy to discuss the biopsy results. Her BP today is 141/90 mm Hg. On physical examination, a malar rash is noted over her face. She has 1+ pedal edema. Her previous laboratory studies include ANA titer of 1:640 and anti-dsDNA titer of 1:320, and a 24-hour urine protein of 3.2 g. The biopsy reveals diffuse proliferative glomerulonephritis. **The treatment option that has been shown to have the most benefit for preserving her renal function is:**

- A) Glucocorticoids
- B) Cyclophosphamide
- C) Plasmapheresis, cyclophosphamide, and glucocorticoids
- D) Cyclophosphamide with glucocorticoids
- E) Azathioprine

117. You are a hospitalist called to admit a 70-year-old man to the ICU. His wife states that he was sitting at the table eating breakfast with her when he dropped his fork and had difficulty speaking. Within a couple of minutes he was unable to move his right side. She called the paramedics, who brought him to the hospital. Now in the ICU, his vital signs are as follows: BP 200/98 mm Hg, HR 100, RR 10, O₂ saturation 94% on room air. He is afebrile. On physical examination he is lethargic and unable to speak. His pupils are equal and round but sluggish. He has flaccid paralysis of the right arm and leg with a Babinski sign present on the right. His heart is irregularly irregular, and an ECG confirms atrial fibrillation. A CT of the head shows a large bleed in the left frontoparietal area with mass effect and midline shift. You decide to intubate the patient to protect his airway. **What is the next most appropriate step in the treatment of this patient while you are awaiting your urgent neurosurgical consult?**

- A) Hyperventilate the patient to a goal pCO₂ of 20 mm Hg
- B) Give a bolus of IV mannitol
- C) Give a bolus of IV dexamethasone
- D) Give sublingual nifedipine to decrease the BP
- E) Anticoagulate with IV heparin because of the atrial fibrillation

118. A 76-year-old man presenting with dysphagia was found to have inoperable esophageal adenocarcinoma. He has an endoscopically placed esophageal stent for palliation of his symptoms, but unfortunately found it very painful, and it was removed a few days later. There is no perforation. He asks whether there are any other treatment options to help with his symptoms. **Which of the following modalities is an appropriate first-line treatment option to discuss?**

- A) Band ligation
- B) Botulinum toxin injection
- C) Brachytherapy
- D) Local ethanol injection
- E) Photodynamic therapy

119. A 48-year-old man is admitted through the ER with a possible left lower extremity cellulitis. The patient says that he has been having fever, swelling, and redness of his left lower extremities that comes and goes spontaneously over the past couple of months. He also tells you about an episode in which he lost vision in his left eye for several minutes a couple of weeks ago, but the vision returned without incident. He had a urologic evaluation for penile trauma 3 months ago. On physical examination, his BP is 125/80, HR 70, RR 14, and he is currently afebrile. His examination is significant for a 3/6 systolic murmur heard at the left lower sternal border without radiation while lying supine. Blood cultures return positive results for *Enterococcus* species, and an echocardiogram reveals large mitral vegetation. You review treatment for enterococcal endocarditis. **Which of the following antibiotics always misses enterococcal infections?**

- A) Ampicillin-sulbactam
- B) Nitrofurantoin
- C) Cefipime
- D) Vancomycin
- E) Linezolid

120. A 70-year-old woman with a history of type 2 DM and CAD with a known left bundle branch block on ECG is admitted to the ICU with sepsis from a urinary source. She is fluid resuscitated, and empiric broad-spectrum antibiotics are begun after the appropriate cultures are obtained. Despite what appears to be adequate resuscitative efforts with volume replacement, the patient has had minimal urine output over the past couple of hours. You decide to place a pulmonary artery catheter to help to determine the patient's hemodynamic situation. **Which of the following complications of pulmonary artery catheter placement is the patient at increased risk for because of her past medical history?**

- A) Pulmonary artery perforation
- B) Pulmonary infarction
- C) Complete heart block
- D) Pneumothorax
- E) Ventricular tachycardia

DR. FAHMI KHAN

B: For each question below determine which answer is true or false

121. Treatment of hypertension: the following statements are true

- A) Monotherapy with 24-hours duration and once-daily dosing agent is preferred
- B) Consider using low-dose combination therapy instead of higher doses of a single agent, to minimize dose-dependent side effects
- C) avoid or minimize dose of diuretics in patients with gout
- D) Always consider a diuretic in any patient needing three or more drugs
- E) Loop diuretics should be used only when thiazide diuretics are likely to be inadequate (i.e., congestive heart failure or Stage 4 CKD).

122. Clinical presentation of Hodgkin's lymphoma

- A) Nodes are usually painless and rubbery
- B) Most common sites are neck and mediastinum
- C) Hodgkin lymphoma starts at a single site within the lymphatic system and then progresses to adjacent lymph nodes
- D) Alcohol-induced pain is a frequent symptom
- E) B symptoms are rare

123. The following are characteristic complications of infection with *Plasmodium falciparum*:

- A) Acute renal failure
- B) Diarrhea
- C) Pulmonary edema
- D) Coma
- E) Acute acalculous cholecystitis

124. Which of the following neoplasms are associated with an increased incidence among HIV-infected patients?

- A) Anal carcinoma
- B) Hodgkin's disease
- C) Non-hodgkin's lymphoma
- D) Nasopharyngeal carcinoma
- E) Cervical carcinoma

125. The following associations about drug mode of action are correct

- A) Leflunomide- Inhibits pyrimidine synthesis; anti-inflammatory; anti-proliferative
- B) Cyclophosphamide- Cross-links DNA; blocks cell division
- C) Cyclosporine- Binds calcineurin, inhibits nuclear factor of activated T cells; early events in T-cell activation
- D) Tacrolimus (FK506)- Binds tacrolimus-binding protein; inhibits nuclear factor of activated T cells; early events in T-cell activation
- E) Sirolimus FTY720- Blocks T-cell proliferation, Analogue of sphingosine 1-phosphate; inhibits lymphocyte homing

126. The following clinical features of restrictive cardiomyopathy are not found in constrictive pericarditis

- A) Atrial fibrillation
- B) Left ventricular hypertrophy
- C) Conduction abnormalities on ECG
- D) Prominent apical impulse
- E) Raised JVP with prominent x and y descents

127. The following are characteristic of *Listeria monocytogenes* infection:

- A) Ingestion of contaminated food is the source of most human infection
- B) Pregnant women account for 30% of all listeriosis cases
- C) The incubation period for invasive listeriosis average 30 days
- D) *L. monocytogenes* is the most common cause of bacterial meningitis in persons 60 years of age or older
- E) Serologic testing (antibody to listerolysin O) is the most effective means of diagnosing listeriosis

128. The following are recognized complications of chronic renal failure

- A) Dementia
- B) Hepatitis E
- C) Infertility
- D) Arthropathy
- E) Gout

129. The long QT syndrome is associated with

- A) Hypercalcemia
- B) Hypokalemia
- C) Aminophylline
- D) Sotalol
- E) Chlorpromazine

130. Causes of gastroparesis include

- A) Scleroderma
- B) Diabetes mellitus
- C) Hypercalcemia
- D) Hypocalcemia
- E) Anticholinergic agents

131. Drugs that decrease theophylline clearance include

- A) Phenytoin
- B) Phenobarbital
- C) Rifampicin
- D) Carbamazepine
- E) Frusemide

132. Membranous nephropathy

- A) May occur as a result of systemic illness or be a primary disorder
- B) Merits an evaluation for malignancy when found in a patient older than age 50 years
- C) Infrequently improved without treatment
- D) Does not recur in the transplanted kidney
- E) Is the most common cause of idiopathic nephrotic syndrome

133. Which of the following physical findings have been associated with sarcoidosis?

- A) Cranial nerve palsy
- B) Angina
- C) Heart block
- D) Uveitis
- E) Digital clubbing

134. The following statements about chronic ambulatory peritoneal dialysis (CAPD) are true:

- A) Relatively reduced peritoneal surface limits the usefulness of the approach in children
- B) Insulin-dependent diabetics have severe problems with glycemic control because of the large amounts of dextrose absorbed from the peritoneal dialysate
- C) The dialysis prescription is tailored to the characteristics of the patient's peritoneal membrane
- D) Fluid removal is adjusted by changing the concentration of dextrose in the dialysate
- E) Peritonitis is a common problem with CAPD and is usually caused by gram-negative organisms

135. Which of the following statements about *Pneumocystis jiroveci* is/are true?

- A) Only HIV-infected patients with low CD4 lymphocytes (<200 cell/mm³) are at risk for *Pneumocystis jiroveci* infection
- B) Pneumothorax is a common complication of *Pneumocystis jiroveci pneumonia* (PJP)
- C) Glucocorticosteroids are warranted in selected patients with PJP
- D) TMP-SMX is the treatment of choice for acute disease
- E) Clinician can consider withdrawing primary prophylaxis against PCP in HIV-infected patients with a sustained response to potent HIV therapy (CD4 <200cell/mm³ with stable low plasma HIV RNA levels)

136. A 37-years-old woman has difficulty swallowing. Over the last 4 years, she has had several episodes of food sticking in the lower esophagus, which were relieved by drinking water. For the last 6 months, she has had difficulty swallowing both solid and liquid and has lost 5 kg of body wt. Barium swallow showed tapering of the distal esophagus and dilatation of the proximal esophagus. Which of the following tests can be used in diagnosis?

- A) Upper GI endoscopy
- B) CT of the chest
- C) MRI of the chest
- D) Bernstein test (acid perfusion test)
- E) Esophageal motility study

137. Concerning ascariasis, the following(s) is/are true:

- A) Albendazole and pyrantel are the treatment of choice
- B) During the pulmonary phase, larvae are abundant in sputum
- C) Obstructive jaundice is a rare event
- D) High worm loads have been associated with stunting of growth in children
- E) Adult worm frequently spontaneously passes per rectum

138. In Carpal Tunnel syndrome the following(s) is /are correct:

- A) Often bilateral in Amyloidosis
- B) A recognized cause of wasting of abductor pollicis brevis
- C) Phalen's sign is pathognomonic
- D) A possible cause of pain in the forearm
- E) Associated directly with diabetes

139. Nystagmus:

- A) Vertical nystagmus usually indicates a lesion of the medulla oblongata
- B) Horizontal nystagmus is usually ipsilateral to an irritative lesion of the labyrinth
- C) Ataxic nystagmus indicates a lesion of the medial longitudinal bundle
- D) May be absent in a lesion of the cerebellar vermis (the central part)
- E) Pendular nystagmus may indicate partial blindness

140. A 31-year-old man presented with fever, headache and constipation for 7 days. On examination he was found to be feverish with temperature of 39.9°C, BP 110/70 mmHg. Spleen is just palpable and tender. His investigations show WBC 2200/mm, Hb 11.9 g/dl. Blood film for malaria is negative. Widal test for typhoid showed, agglutinating antibody titer to 0 of 1:320.

Regarding the above patient, the following(s) is/are **TRUE**:

- A) Epistaxis is a recognized feature
- B) Rose spot is an expected finding on the first week
- C) Doxycycline is effective in the treatment of this patient
- D) Pancreatitis is a recognized feature
- E) The relapse rate is high following appropriate treatment

141. The following statements about UTI are true:

- A) Frequency, urgency and dysuria are associated with cystitis
- B) Asymptomatic bacteriuria in pregnancy need not to be treated.
- C) Chills fever, nausea and vomiting are usually associated with pyelonephritis
- D) Inability to identify bacteriuria by light microscope excludes urinary tract infection
- E) Sterile pyuria rules out the possibility of renal abscess

142. Stroke:

- A) Cerebral hemorrhage accounts for more than 40% of acute strokes
- B) In supratentorial strokes with homonymous hemianopsia, patients cannot see on the hemiplegic side
- C) Vertigo, vomiting, dysphagia, and Horner's syndrome indicate occlusion of the vertebrobasilar circulation
- D) Pinpoint pupils and bilateral upgoing plantars could signal a brainstem stroke
- E) Carotid endarterectomy should be considered for patients with more than 70% stenosis because this is more effective than medical treatment

143. Helicobacter pylori:

- A) Causes ulceration in the duodenum
- B) Causes Barrett's metaplasia in the esophagus
- C) Is associated with hypergastrinaemia
- D) Is often resistant to certain antibiotics
- E) Can convert urea to ammonia and carbon dioxide

144. Unilateral facial weakness is a recognized feature of:

- A) Herpes zoster infection
- B) Motor neuron disease
- C) Acoustic neuroma
- D) Cholesteatoma
- E) Syringomyelia

145. Clinical manifestations of pseudohypoparathyroidism include:

- A) Hypocalcaemia that does not respond to vitamin D and calcium supplementation
- B) Low serum levels of parathyroid hormone
- C) Exaggerated response of urinary cyclic AMP to PTH injection
- D) Short stature
- E) Normal intellect

146. The following are reliable indices of iron deficiency:

- A) Serum ferritin below 15 µg/l
- B) MCHC below 30 g/dl
- C) MCH below 25 g/dl
- D) Absence of stainable iron in a marrow biopsy
- E) Raised free erythrocyte protoporphyrin

147. The following radiological findings are matched with the correct diagnosis:

- A) Hilar lymphadenopathy with “eggshell” calcification- Silicosis
- B) Pleural thickening and diaphragmatic calcification-Asbestosis
- C) Central bronchiectasis- Chronic Eosinophilic Pneumonia
- D) Tram-tracking-Bronchiectasis
- E) The “radiologic negative” of pulmonary edema- Allergic Bronchopulmonary Mycosis

148. The following statements about malignancies arising from unknown primary site are correct.

- A) Usually, systemic therapy is beneficial if the primary site is identified
- B) Chemotherapy does not improve survival compared to palliative therapy
- C) When squamous cell carcinoma is identified in the cervical lymph nodes the patient is presumed to have primary head and neck cancer
- D) Midline mass in the mediastinum should be investigated for extragonadal germ cell tumors
- E) Radiation therapy may be curative in squamous cell carcinomas of the head and neck

149. Fresh frozen plasma (FFP)

- A) it contains all factors
- B) intravenous administration can lead to volume overload
- C) viral transmission is possible with transfusion
- D) it is a first-line treatment for uremic patients with bleeding
- E) it is a first-line treatment for bleeding patients with a coagulopathy

150. Outcome from bacterial meningitis relates to:

- A) Age of patient
- B) Time to first administration of antibiotic
- C) Development of antibiotic resistance during therapy
- D) The causative organism
- E) Development of complications

151. Subtypes of Hodgkin’s lymphoma

- A) Lymphocyte-rich is most common
- B) Mixed cellularity is next in rank of frequency
- C) Nodular sclerosis is rare
- D) Lymphocyte depleted is most common
- E) Nodular lymphocyte-predominant Hodgkin lymphoma is a distinct entity with unique clinical features and a different treatment paradigm

152. Hypertrophic cardiomyopathy

- A) Is a recognized cause of sudden death
- B) May be associated with thiamine deficiency
- C) Is commonly associated with mitral regurgitation
- D) Has a recognized association with ACE gene polymorphism
- E) Is familial in 50% of cases

153. Risk factors for the development of reactivation infection with *M. tuberculosis* include:

- A) Race
- B) Malnutrition
- C) Silicosis
- D) Chronic renal failure
- E) Age

154. Disseminated intravascular coagulation

- A) Is often characterized by a neurological presentation
- B) Responds to heparin therapy in the majority of cases
- C) May be caused by an ABO incompatible transfusion
- D) Is characterized by raised fibrinogen levels
- E) Is associated with thrombocythemia

155. Features of magnesium depletion include:

- A) Hypokalemia
- B) High serum parathyroid hormone level
- C) Prolongation of the PR and QT intervals
- D) Amelioration of cardiac toxicity
- E) Can occur with aminoglycosides administration

156. In mitral incompetence:

- A) Myxedematous degeneration is common cause
- B) Doppler examination is sufficient for exact determination of the severity
- C) Repair is recommended rather than replacement in non-rheumatic form
- D) Ejection fraction can be supernormal
- E) Asymptomatic patient with left ventricular dysfunction warrant surgery

157. Regarding cellulites the following is/are true:

- A) Caused by flora colonizing the skin and appendages
- B) Specific bacterial etiology is difficult to establish
- C) Lower limbs venous insufficiency is predisposing factor
- D) *Pseudomonas aeruginosa* is the usual pathogen in neutropenic patients
- E) Penicillin treatment is adequate in streptococcal associated cellulitis

158. The physical signs of an uncomplicated large pneumothorax include:

- A) The trachea deviated to the opposite side
- B) A clicking sound synchronous with the heartbeat
- C) Symmetrical expansion of the chest
- D) Increased breath sounds over the pneumothorax
- E) Increased percussion note over the pneumothorax

159. In respiratory failure:

- A) Type I failure results in a partial pressure of oxygen (pO_2) <8 kPa and a partial pressure of carbon dioxide (pCO_2) of >6.5 kPa
- B) In respiratory failure associated with chronic bronchitis, the level of carbon dioxide (CO_2) determines the respiratory rate
- C) Respiratory failure as defined in (a) would be an indication for ventilation in pure asthma
- D) Doxapram is a respiratory stimulant used in respiratory failure associated with chronic obstructive pulmonary disease
- E) The main aim in type II failure is to keep the $pO_2 >7.0$ kPa without worsening of the acidosis or pCO_2

160. An asymptomatic 56-year-old woman was found to have splenomegaly. The spleen was 3 cm below the costal margin. The CBC revealed the following: Hb 12.9 g/dl; hematocrit 39; MCV 72 fL. Total RBC count 5.450.00/mm³; platelet count 5,000/mm³; WBC 16.000/mm³. The differential of the CBC count was within normal limit. The ESR was 0. Regarding the underlying disease, the following statement(s) is/are **TRUE**:

- A) Erythromelalgia is a recognized complication
- B) Low plasma erythropoietin is typical feature
- C) Hemoglobin A2 is raised in the majority of patient
- D) The medial survival of the pt is less than 5 years
- E) Interferon therapy reduces the spleen size

161. A 24-year-old woman presents with two days history of fever, sore throat and marked malaise, she had hyperthyroid Grave's disease diagnosed two months back and on therapy with carbimazole 40mg/day and propranolol 120mg per day. On P/E: P: 120/min, BP: 110/60, T: 39.2C. She had diffuse moderate enlargement of the thyroid gland. Labs: total leukocytes count of 900, Absolute granulocyte count 215, Hb 12.2, platelet count 234000/ μ l. Serum bilirubin is 1.1mg/dl and SGOT 12, SGPT 22. **Appropriate management of this patient includes:**

- A) Administration of broad spectrum antibiotic
- B) Administration of high dose of prednisone
- C) Substitute propylthiouracil for carbimazole
- D) Administration of granulocyte colony stimulating factor
- E) Administration of human immunoglobulin

162. Heart failure:

- A) The clinical features of left heart failure include: tachycardia, basal crepitations, pulsus alternans and a raised JVP
- B) Congestion of the pulmonary veins alone does not result in orthopnea
- C) Chronic congestive heart failure leads to secondary hyperaldosteronism
- D) Causes of heart failure include ischemic heart disease, hypertension, and thiamine deficiency
- E) Clinical features of right heart failure include a raised JVP, ankle edema, and hepatomegaly

163. Oral corticosteroids:

- A) Is an effective treatment for SLE
- B) In the long term may cause cataracts
- C) Should be avoided in sarcoidosis because they induce pulmonary edema
- D) May be stopped abruptly after 2 weeks of 40 mg prednisolone daily in patients who are not exposed to repeated courses.
- E) May reveal that 15% of patients labelled as having chronic bronchitis, in fact have reversible airways disease.

164. The following are indications for anticoagulating a patient who has atrial fibrillation with warfarin:

- A) Age under 60 years
- B) Associated mitral stenosis
- C) Atrial fibrillation of more than 24 hours' duration
- D) A history of cerebral thromboembolism
- E) Associated left ventricular failure

165. Concerning papilledema:

- A) There is loss of venous pulsation on Fundoscopy
- B) There may be enlargement of the blind spot
- C) Intracranial pressure may be normal
- D) Hypocalcaemia is a recognized cause
- E) It is a recognized feature in Guillain-Barré syndrome

166. A 30-year-old diabetic woman with ischemic heart disease, chronic psychotic disorder and urinary tract infection had liver function tests that showed a cholestatic picture. **Drugs that could have contributed to cholestatic liver disease include:**

- A) Aspirin
- B) Sulphonylureas
- C) Erythromycin estolate
- D) Chlorpromazine
- E) Nitrofurantoin

167. A 23-year-old man known to be cocaine abuser brought to the ER with palpitation, chest pain and euphoria. On examination: pulse 110/min, BP 150/110 mmHg. ECG revealed sinus rhythm with depressed ST segment and inverted T wave in precordial lead. **Regarding the above patient the following is/are TRUE:**

- A) Cardiac manifestation occur exclusively following IV use of cocaine
- B) Serum cardiac troponin levels are more sensitive than CPK for the diagnosis of MI
- C) Calcium Channel blockers are contraindicated in treatment of Myocardial ischemia
- D) Intracerebral Hemorrhage is a recognized complication
- E) Prazosin is useful in the control of hypertension

168. Regarding Anti-TB treatment, the following(s) is/are true:

- A) Pyrazinamide (PZA) and Rifampicin (RMP) are potent bactericidal and sterilizing anti-TB agents
- B) Short course chemotherapy means 4 anti-TB drugs for 6 months duration
- C) Pyrazinamide and streptomycin should not be included in treating pregnant females
- D) PZA and RMP are among the agents which cross readily blood train barrier to the CSF
- E) Immuno-thrombocytopenia is a strong indication to discontinue RMP

169. Recognized effects of PEEP include:

- A) Sodium retention
- B) Fall in cardiac output
- C) Rise in closing volume
- D) Rise in FRC
- E) Fall in CVP

170. Acholuric jaundice without pain:

- A) Is a common presentation of pancreatic carcinoma
- B) Is a feature of Gilbert's disease
- C) Can occur in hereditary spherocytosis
- D) Is associated with pale-colored stools
- E) Is associated with pruritus

171. Regarding UTI, the following is /are true:

- A) Urine culture and sensitivity should be done in all patients
- B) Relief of symptoms does not always indicate bacteriological eradication
- C) Recurrence of cystitis often results from persistent vaginal colonization
- D) community acquired infections are due to antibiotic sensitivity bacteria
- E) 3 days treatment with ciprofloxacin or sulfa-trimethoprim is the treatment of choice for pyelonephritis

172. The following associations are correct:

- A) Anti-smith antibody--- systemic lupus erythematosus
- B) Anti-SSA antibody--- Sjogren's syndrome
- C) Anti-ribonucleoprotein antibody--- mixed connective tissue disease
- D) Anti-centromere antibody--- CREST syndrome
- E) Anti-SBB antibody-Sjogren's syndrome

173. The following statements about the management of pulmonary embolism are correct:

- A) Intravenous anticoagulation should not be started until definitive diagnosis is made
- B) Oral warfarin therapy is overlapped with intravenous heparin therapy
- C) Inferior vena cava interruption is considered in patients with recurrent emboli despite adequate anticoagulation
- D) Thrombolytic therapy should be considered in patients who are hemodynamically unstable following massive acute embolism
- E) Pulmonary embolectomy should be considered in all patients with proven pulmonary emboli

174. The following host immunity is associated with appropriate infection:

- A) Neutropenia--- hepatosplenic candidiasis
- B) Decreased cell mediated immunity--- L. pneumophila in a renal transplant patient
- C) Immunoglobulin A deficiency--- chronic giardiasis
- D) Complement deficiency--- recurrent meningococcal disease
- E) Asplenia--- severe babesiosis

175. Hypertension in diabetes:

- A) Is more prevalent in type 1 than in type 2
- B) Its treatment slows the deterioration of nephropathy in type 1 DM
- C) Thiazide diuretics should not be used in diabetes
- D) Beta-blockers may increase the risk of severe hypoglycemia in insulin-treated patients
- E) Increases the risk of stroke in diabetes

176. The following are potential causes for CD4 cell depletion in HIV-infected person:

- A) Apoptosis
- B) Syncytia formation
- C) Autoimmune destruction
- D) Direct toxicity of HIV
- E) Impaired regeneration

177. Which of the following statements about lupus anticoagulant are correct?

- A) It is an antiphospholipid antibody that interferes with coagulation
- B) Most patients with lupus anticoagulant do not have lupus (SLE) or a clinical bleeding disorder
- C) Affected patients are at risk for arterial and venous thrombosis
- D) Affected women may have recurrent fetal loss
- E) it is associated with a normal PTT

178. In insulin treatment:

- A) Pen injectors are reserved for the small minority who take four or more injections per day
- B) Only patients who cannot be controlled with once-daily insulin should have two or more injections
- C) Insulin should be started without delay in a thin hyperglycemic patient with ketonuria
- D) Insulin may sometimes be needed during short periods of illness in patients with type 2 DM
- E) All patients on insulin should be discouraged from changing their doses without first checking with the doctor or nurse

179. In Zollinger-Ellison syndrome

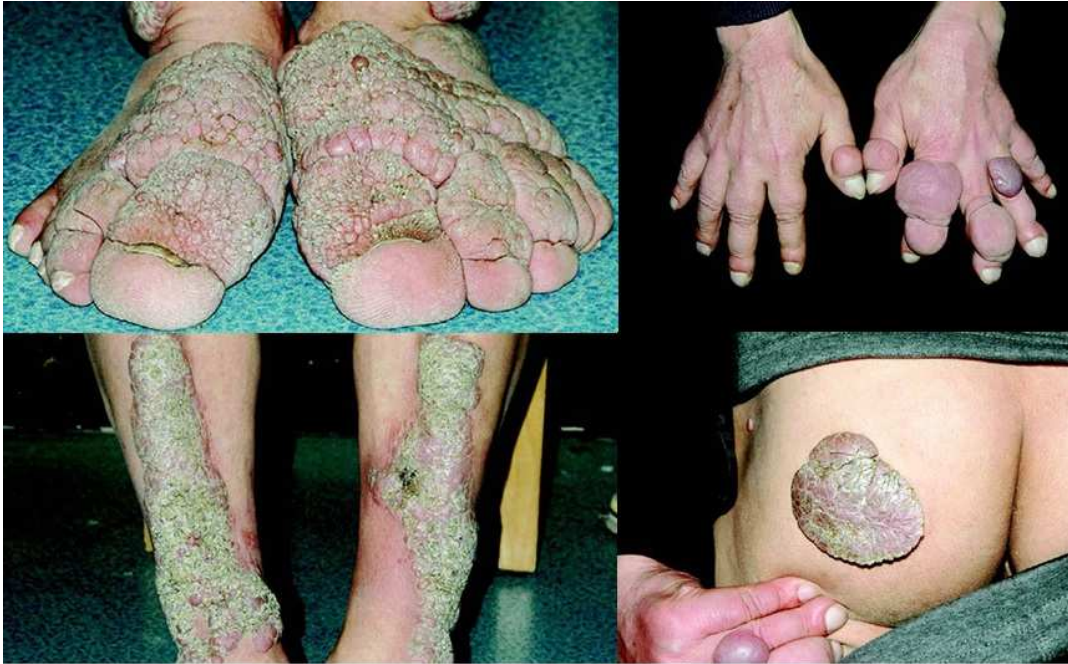- A) There is an association with acromegaly
- B) There is excessive gastrin secretion in the stomach
- C) Diarrhea is a common feature
- D) Treatment is usually medical
- E) The tumour is usually benign

180. The following statements are true:

- A) Tylosis is associated with achalasia
- B) On barium swallow, a 'bird's beak' appearance is suggestive of squamous carcinoma
- C) Pneumatic dilatation is the treatment of choice for achalasia
- D) Reduced lower esophageal sphincter pressure is a common feature of gastro-esophageal reflux disease
- E) Esophageal pH is usually less than 4

C. Each slide followed by best of five question, Choose the best answer

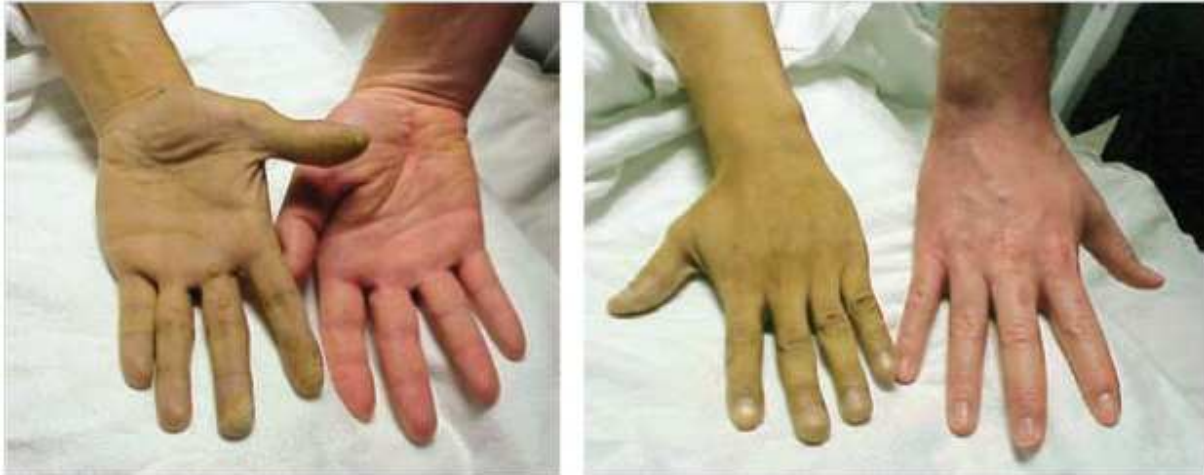181. A 61-year-old man presented with bilateral, asymptomatic, indurated non-pitting verrucous plaques and nodules on his extremities and buttocks. He was diagnosed with Graves' disease 20 years ago and diabetes mellitus 10 years ago.



What is the diagnosis?

- A) Streptococcus lymphedema
- B) Rheumatoid nodule
- C) Myxedema
- D) Erythema elevatum diutinum
- E) Necrobiosis lipoidica diabeticorum

A patient with human immunodeficiency virus had a rash in association with trimethoprim-sulfamethoxazole used as prophylaxis for *Pneumocystis carinii* pneumonia. An alternative medication was used, but the patient took 3 times the normal dose by mistake. He became dyspneic, and headache, nausea and vomiting, and the skin discoloration shown here developed (a normal hand is shown for contrast on the right).



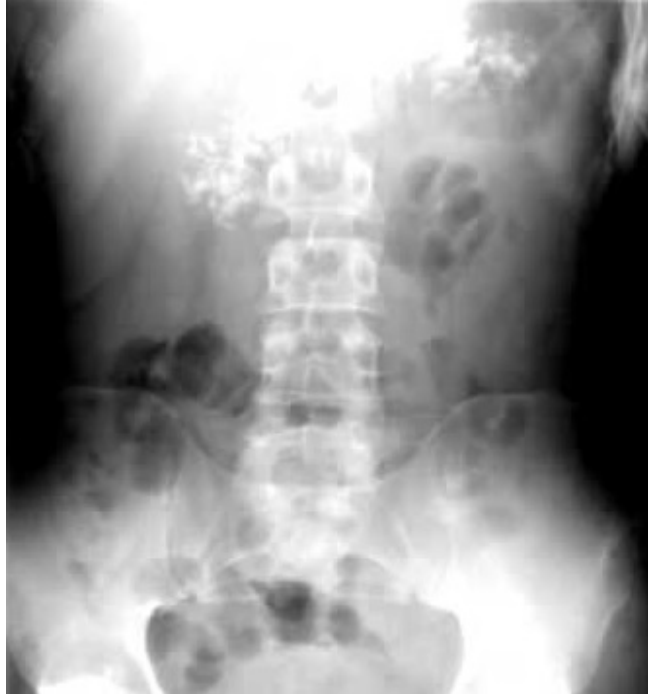182. What was the alternative medication?

- A) Pentamidine
- B) Pyrimethamine-sulfonamide
- C) Atovaquone
- D) Dapsone
- E) Clindamycin-primaquine

183. In addition to supplemental oxygen, which one of the following would be the most appropriate antidote?

- A) *N*-Acetylcysteine
- B) Amyl nitrite
- C) Methylene blue
- D) Deferoxamine
- E) 4-Methylpyrazole

A 38-year-old white woman with an 18-year history of heavy alcohol use presents with nausea and epigastric pain radiating to the back worsened by eating for 2 weeks. Plain x-ray film of the abdomen is seen below. Upper endoscopy shows nonspecific "gastritis."



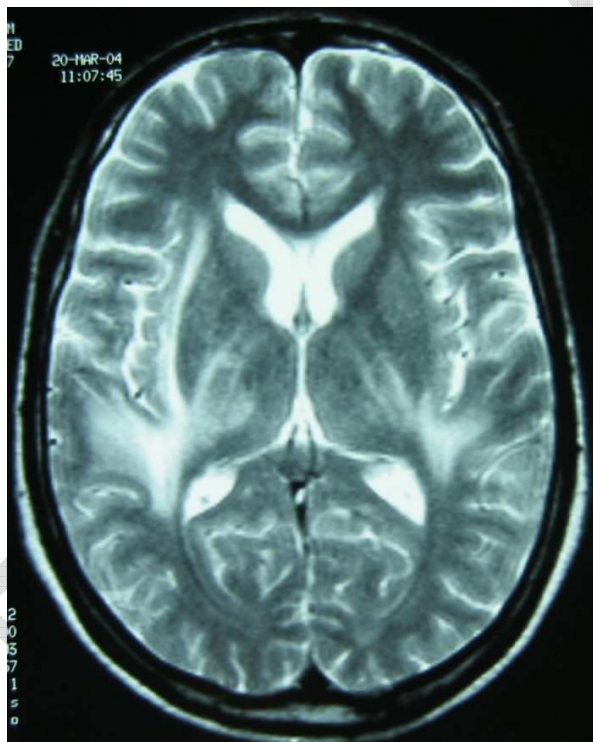
184. What is the likely diagnosis?

- A) Mesenteric Artery Ischemia
- B) Cholangitis
- C) Chronic pancreatitis
- D) Chronic cholecystitis
- E) Pancreatic cancer

185. Which of the following is indicated to confirm the diagnosis?

- A) Abdominal CT scan
- B) ERCP
- C) Secretion test with duodenal aspiration
- D) Stool trypsin concentration
- E) No further testing is necessary

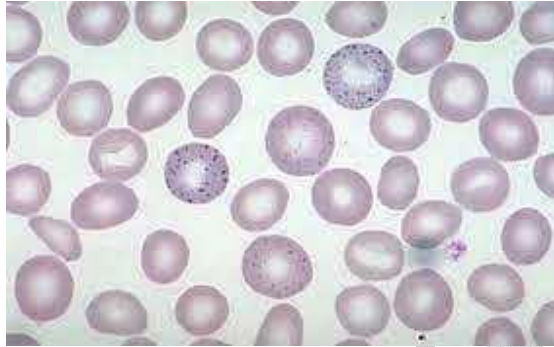
186. A 15-year old girl presents with a rapidly progressive paralysis and encephalopathy. She had a mild viral-like illness for the preceding week, with lethargy. Over the days preceding presentation she developed back pain and difficulty in walking. On the day of admission, she develops a headache, vomiting, a fluctuating level of consciousness and become unable to move her limbs. Neurological examination shows an encephalopathic girl, with four limb paralysis, absent deep tendon and abdominal reflexes, and mild bilateral facial weakness. A high thoracic (C4) sensory level, severe urinary retention and stool incontinence is evident. Systemic examination does not reveal pyrexia, rash, lymphadenopathy, hepatosplenomegaly or sepsis. CSF study reveals an opening pressure of 20, with cerebrospinal fluid (CSF) containing 0 red blood cells, 47/ μ l white blood cells of which 85% were lymphocytes, glucose of 52 mg/L, and protein of 114 mg/dL and CSF cultures are negative. Initial MR imaging is seen below.



What is the most likely diagnosis?

- A) Meningioma
- B) Lymphoma
- C) Parkinson disease
- D) Acute disseminated encephalomyelitis
- E) Bilateral MCA infarction

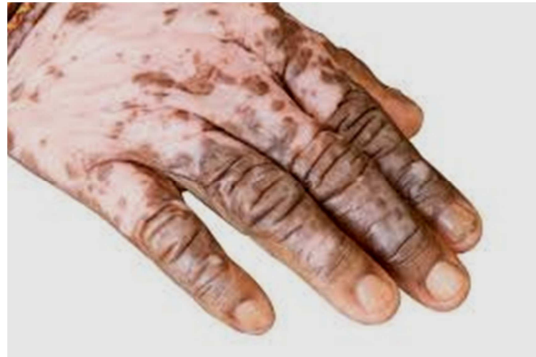187. A 60-year-old woman presents to her primary care physician for her annual physical examination. She says she has been feeling “down” and tired lately. Upon questioning, she also admits to some constipation, abdominal pain, joint pain, and muscle aches. Relevant laboratory findings are as follows: Hemoglobin: 9.0 g/dL; Hematocrit: 26%; Mean corpuscular volume: 76 fL; WBC count: $5 \times 10^9/L$. Coombs test is negative, reticulocyte count is low and hemoglobin electrophoresis is normal. Peripheral blood smear is shown below.



What is the most likely diagnosis?

- A) Lead poisoning
- B) Hemolysis
- C) Thalassemia
- D) Iron deficiency anemia
- E) Anemia of chronic disease

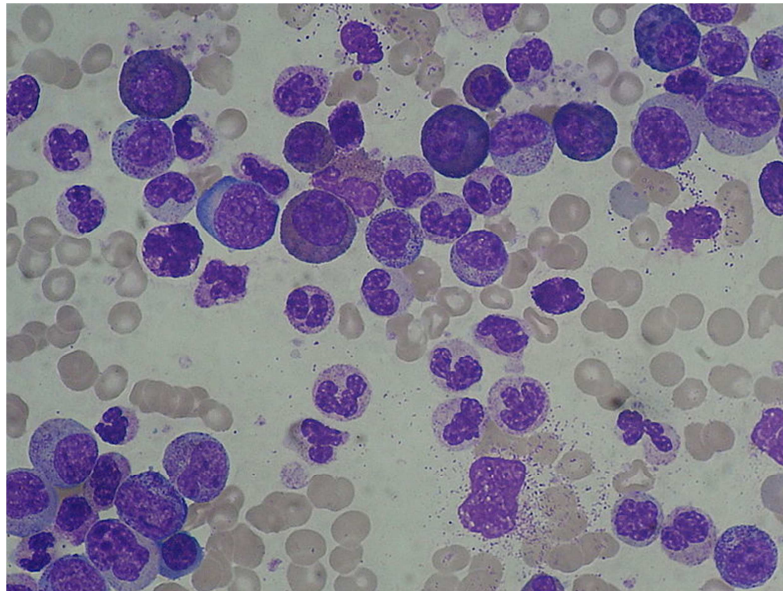
188. A 34-year-old man presents with a 3-month history of depigmented patches of his hand. He says the problem is spreading.



Which of the following conditions has an increased incidence in association with this picture?

- A) Lichen planus
- B) Hyperparathyroidism
- C) Sarcoidosis
- D) Pernicious anemia
- E) hemochromatosis

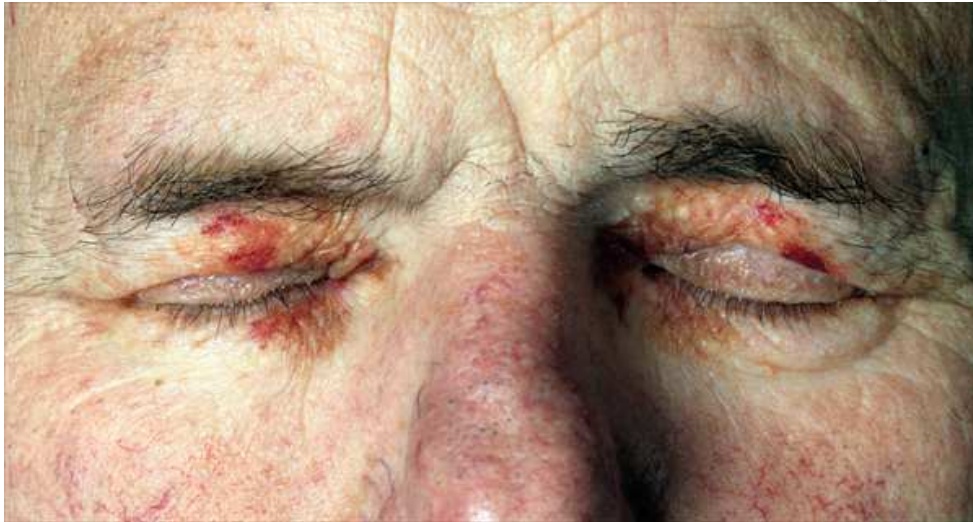189. A 55-year-old woman presents to her primary care physician for a routine physical. She reports an unintentional 14-kg (30-lb) weight loss and chronic fatigue. Abdominal examination reveals an enlarged spleen. Relevant laboratory findings are as follows: Hemoglobin: 12.9 g/dL; Hematocrit: 38.1%; Mean corpuscular volume: 92 fL; WBC count: $167 \times 10^9/L$; Platelet count: $625 \times 10^9/L$; Blood smear is shown below.



What is the likely diagnosis?

- A) Acute myeloid leukemia
- B) Chronic myelogenous leukemia
- C) Acute lymphocytic leukemia
- D) Thrombocythemia
- E) Leukemoid reactions

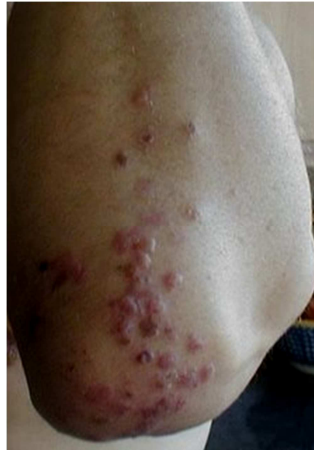190. A 62-year-old man came to our outpatient clinic with purpura on his eyelids. 7 months before, periocular purpura appeared after a minimal trauma. These lesions did not resolve for months. He also reported fatigue over the previous 6 months. On examination pinch purpura between smooth waxy papules were found (figure below). Serum protein electrophoresis showed the presence of a monoclonal (M) protein. Immunofixation of both serum and urine determined its type: IgA- λ -type Bence-Jones protein. Bone-marrow examination was diagnostic for myeloma. Radiography showed small osteolysis of the head and cervical spine. Further investigations showed bilateral carpal tunnel syndrome and cardiac involvement.



What is the most likely diagnosis?

- A) Syringoma
- B) Sarcoidosis
- C) Xanthelasma
- D) Amyloidosis
- E) Necrobiotic xanthogranuloma

A 42-year-old man without prior significant medical history comes to your office for evaluation of chronic diarrhea of 12 months duration, although the patient states he has had loose stools for many years. During this time he has lost 10 kgs (25 lbs). The diarrhea is large volume, occasionally greasy, and nonbloody. In addition, the patient has mild abdominal pain for much of the day. He has been smoking a pack of cigarettes a day for 20 years. His physical examination reveals a thin male with temporal wasting and generalized muscle loss. He has glossitis and angular cheilosis. He has an exquisitely pruritic eruption on the extensor surfaces of the elbows [Figure below].



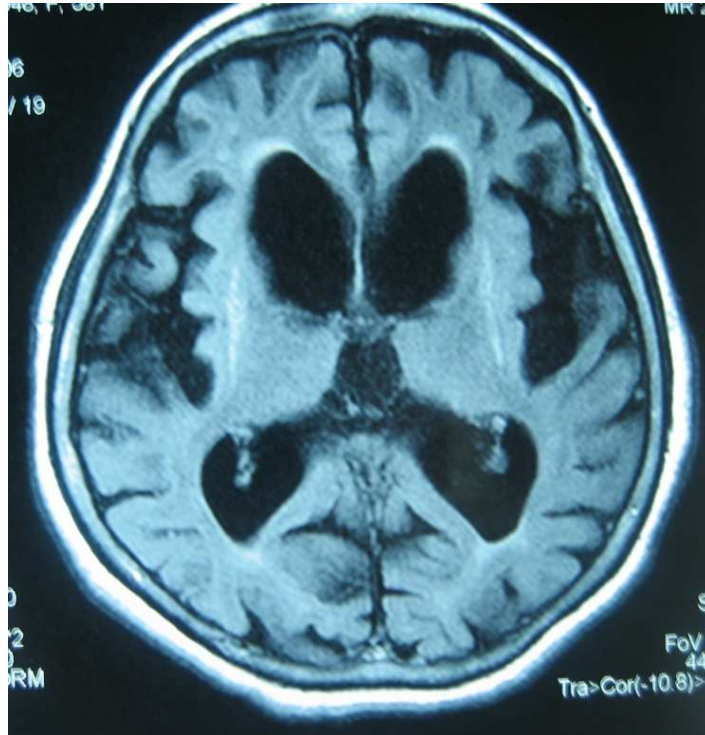191. Which of the following is False about this condition?

- A) IgA tissue transglutaminase (IgA tTG) antibody has 95% sensitivity and 95% specificity for the diagnosis of celiac disease.
- B) Antigliadin antibodies are highly recommended because of their higher sensitivity and specificity.
- C) Biopsy of small intestine reveals complete absence of villi
- D) This patient may have secondary lactase deficiency
- E) This condition is associated with increased incidence of small intestine lymphoma

192. In this patient the diarrhea is secondary to:

- A) Disordered motility
- B) Mucosal damage
- C) Carbohydrate malabsorption
- D) PAS- positive microorganism
- E) Increased concentration of cholecystokinin (released from enterocytes)

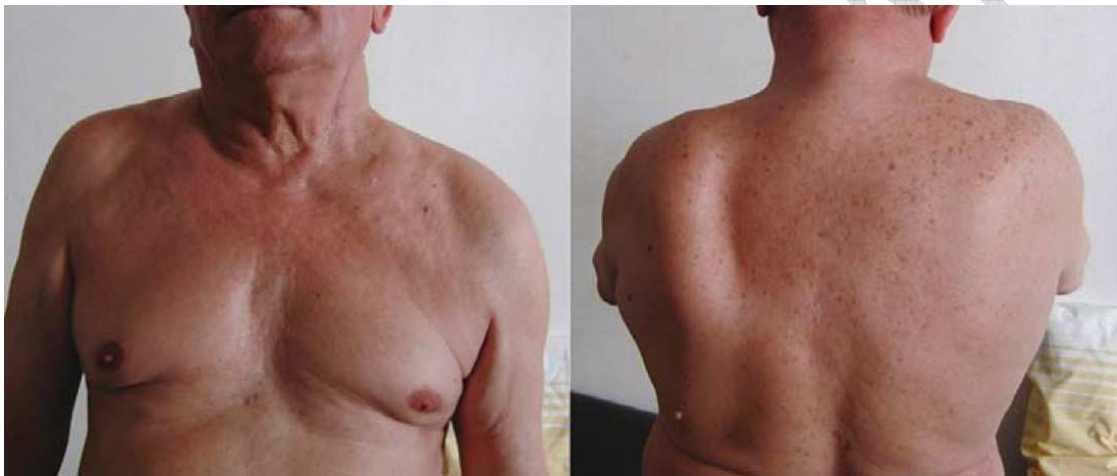193. A 28-year-old female presented to the Medicine OPD with a history of abnormal movements of hands and face of one and a half year duration. These abnormal movements were of gradual onset with progressive course. She also had behavioral changes along with abnormal movements in the form of frequent outbursts of anger, loss of temper, depressive mood, and insomnia. These abnormal movements got aggravated during outbursts of anger, disturbances in mood, and were absent during sleep. Brain CT is shown below.



What is the most likely diagnosis in this patient with abnormal movements?

- A) Normal pressure hydrocephalus
- B) Alzheimer disease
- C) Huntington disease
- D) Neuroacanthosis
- E) Multisystem atrophy

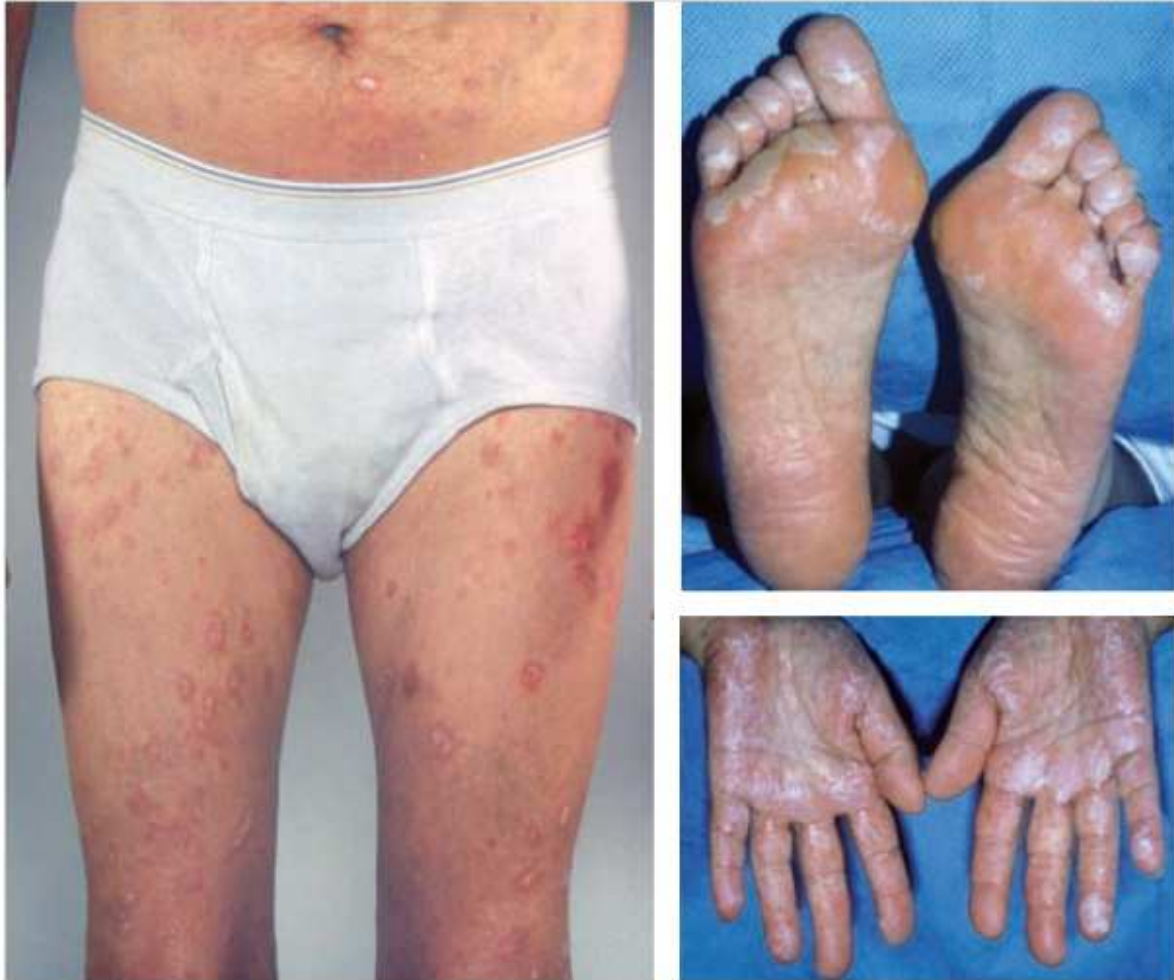194. A 42-year-old man presents to your clinic complaining of a constant dull ache located in the left shoulder girdle and the posterolateral side of the neck, associated with sudden difficulty during overhead activities and heavy lifting. He worked as a heavy manual laborer. There is no history of trauma, falls or any precipitating events. The onsets of his symptoms occur 10 days ago with an acute left-sided neck and shoulder girdle pain. He describes the pain as intermittent and sharp, ranging from 6 to 10 out of 10 on a numeric pain rating scale. The pain is worse during the night, often severe enough to prevent him from sleeping. It radiated to the left periscapular region without any neurological symptoms in the arm. A week later, he noticed weakness of his left shoulder during abduction and anterior elevation, whilst his pain subsided markedly. There were no associated headaches or left upper extremity numbness nor any severe motor weakness. The patient was self-medicated on paracetamol. His past medical history was unremarkable. Physical examination revealed winging of his left scapula, see image below.



The differential diagnosis includes:

- A) Spinal accessory nerve palsy
- B) Long thoracic nerve palsy
- C) Dorsal scapular nerve palsy
- D) All of the above
- E) B&C

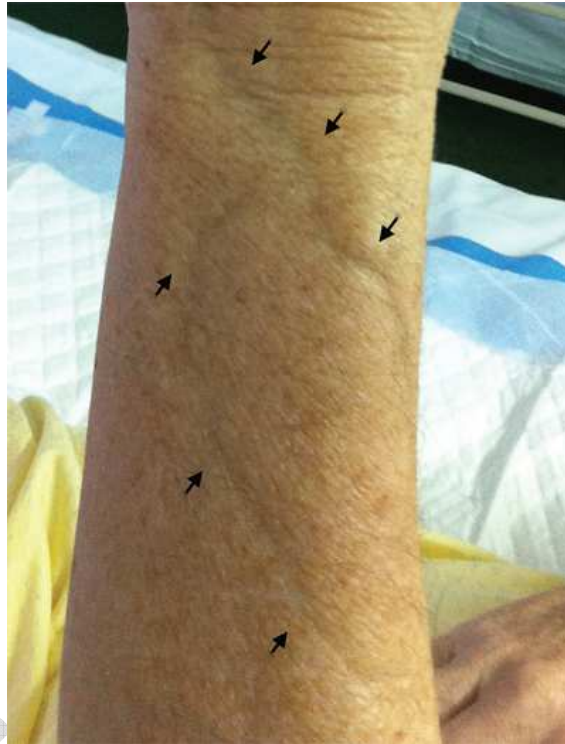195. A 37-year-old man received a bone marrow transplant 2 weeks previously for acute myelogenous leukemia. Two days ago, itching, diarrhea, pain and numbness in his palms and soles, and the skin lesions are [Figure below] developed.



Each of the following statements about this condition is true EXCEPT:

- A) Use of HLA-identical grafts eliminates the risk of this condition
- B) This condition typically occurs 7 to 21 days after transplantation
- C) Increased age is a risk factor for this condition
- D) Sex mismatch (female donor, male recipient) is a risk factor for this condition
- E) Values on liver function tests are often increased in this condition

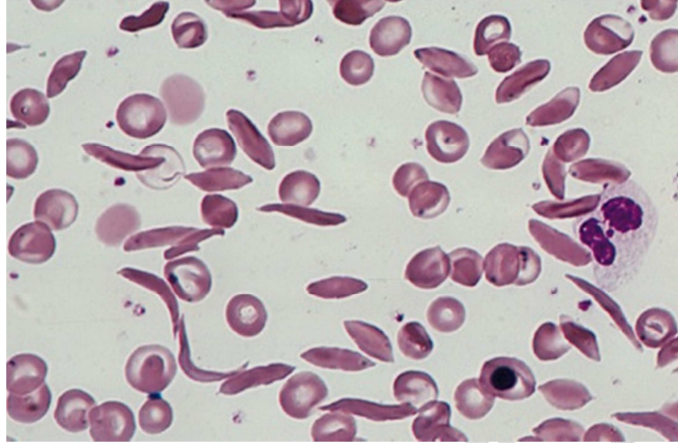
196. A 71-year-old woman with no medical history of note presents to the hospital, with 1 month of joint pain. She also had cutaneous edema with subcutaneous hardening that started in her legs, then spread to the trunk and arms, affecting the distal region of the limbs. On examination she had mild erythema and mild pitting leg edema, and hardening of the subcutaneous tissue of the limb, lumbar, and breast areas. Both forearms showed a linear depression in the skin parallel to the course of the superficial veins, more obvious on raising the arm that was consistent with the groove sign [Figure below].



This clinical sign is most often associated with:

- A) Systemic sclerosis
- B) Eosinophilic fasciitis
- C) Dermatomyositis
- D) Mixed connective tissue disease
- E) Polymyalgia rheumatica

A 21-year-old African female presents with bone pain. She has a chronic anemia. On examination she looks ill with yellowish discoloration of sclera. Temperature 38.0 C, BP 120/60 mmHg, pulse 110/min. abdomen examination shows hepatosplenomegaly. The rest of his examination is unremarkable. Investigations: WBC $11 \times 10^9/L$, hemoglobin 9.0 gm/dL. Peripheral smear is shown below.



197. All of the following are true of Bone Marrow transplantation (BMT) in this patient **EXCEPT**:

- A) Allogenic matched sibling donor BMT has resulted in cure of the diseases
- B) Graft versus host disease is a significant concern
- C) The cost of the procedure is not prohibitive
- D) Access to the procedure may be limited based on locality
- E) Mortality rate is 10%

198. The most common cause of death in patient with this condition is:

- A) Acute chest syndrome (ACS)
- B) Isosthenuria
- C) Septicemia
- D) Stroke
- E) Pulmonary hypertension

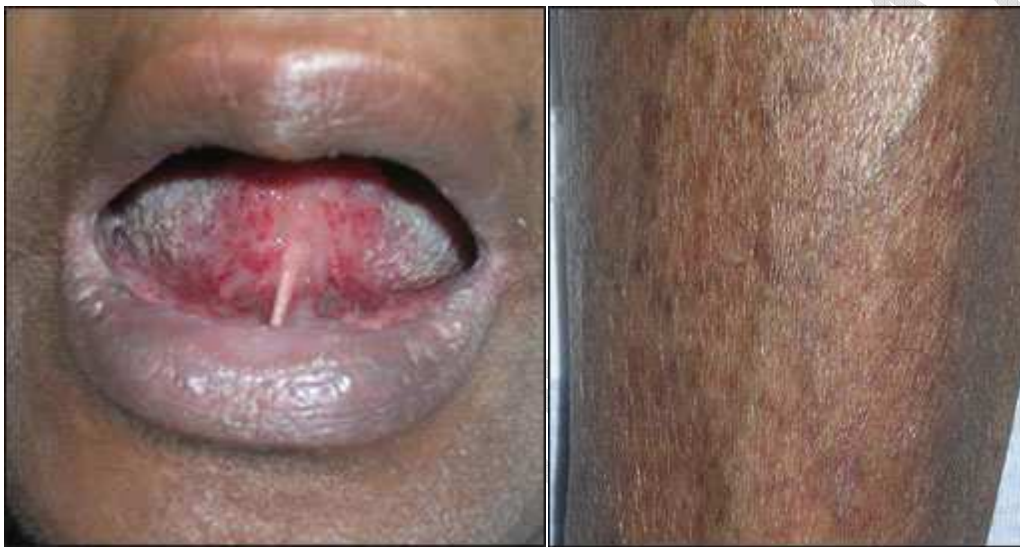
199. An 83-year-old bed bound female, with a history of dementia who had an indwelling urinary catheter in place for last 3 months, presents to emergency department with the complaints of nausea, vomiting, decreased oral intake, chronic constipation, and purplish discoloration of the urine bag and tubing. She has been having these complaints on and off (three times over a period of 1 month) before coming to us and every time she is treated empirically with oral antibiotics (Ceftriaxone) for suspected UTI. Her urinary catheter and bag were changed each time she would get purple discoloration and her symptoms would get better. This time she is hemodynamically stable and was afebrile. Physical examination is unremarkable except for mild dehydration. She is noticed to have purple colored urine in the urine bag, along with purplish discoloration of the tubing and the bag [Figure below]. Investigations revealed a hemoglobin of 12 g/dl and total leukocyte count of 11×10^9 . Her blood urea was 40 mg/dl, serum creatinine 0.9 mg/dL, serum sodium 135 mEq/L, potassium 4.2 mEq/L, chloride 110 mEq/L, and bicarbonate was 20 mEq/L. Her urine dipstick showed a pH of 8.0, specific gravity 1.020, and it was positive for nitrite. Urine microscopy revealed 4-6 leucocytes, 3-5 red blood cells, and triple phosphate crystals. Urine culture was sent and she was started on oral cefixime. Lactulose was also prescribed for relieving constipation.



What is your diagnosis?

- A) Excessive blackberry or beet consumption.
- B) Familial benign hypercalcemia.
- C) Isoniazid use.
- D) Nitrofurantoin use.
- E) Purple urine bag syndrome.

200. A 52-year-old woman presented to the emergency department reporting a 1-week history of rash on her bilateral lower extremities and "spots under her tongue." She noted no similar rashes in the past nor any recent trauma, viral infection, fever, sick contacts, overt bruising, hematuria, melena, hematochezia, epistaxis, gingival bleeding, or menorrhagia. Her medical history included lupus, congestive heart failure, hypertension, hypothyroidism, and anemia of chronic disease. Physical examination revealed petechiae over her bilateral lower extremities as well as palatal and sublingual petechiae. The lesions were asymptomatic and the remainder of her physical examination was normal. Laboratory studies revealed a white blood cell count of $4 \times 10^9/L$ (normal, $4.5-11.0 \times 10^9/L$); hemoglobin of 10.7 g/dL (normal, 12.0-15.0 g/dL), which was a stable level compared with her baseline; hematocrit of 35.9% (normal, 35%-45%); and a platelet count of $6 \times 10^9/\mu L$ (normal, $150-250 \times 10^9/L$). Her liver function tests, Epstein-Barr virus titer, human immunodeficiency virus test, and hepatitis panel were all negative.



What's Your Diagnosis?

- A) Chronic disseminated intravascular coagulation
- B) Idiopathic thrombocytopenic purpura
- C) Leukocytoclastic vasculitis
- D) Meningococemia
- E) Henoch Schönlein purpura

Answer key in the next page, best luck

Paper 11

I: Best answer				II: false or true			
1. D	31. A	61. A	91. E	121. TTTTT	148. TTTTT	175. FTFTT	
2. D	32. D	62. B	92. E	122. TTTFF	149. TTTFT	176. TTTTT	
3. B	33. A	63. D	93. B	123. TTTTT	150. TTFTT	177. TTTTF	
4. D	34. C	64. A	94. E	124. TTTFT	151. FTFFT	178. FFTTF	
5. C	35. D	65. C	95. E	125. TTTTT	152. TFTTT	179. TFTTF	
6. D	36. B	66. B	96. A	126. FTTF	153. TTTTT	180. FFTTF	
7. D	37. E	67. A	97. D	127. TTTFF	154. FFTFF		
8. C	38. C	68. D	98. A	128. TFTTF	155. TFTTT		
9. B	39. D	69. E	99. C	129. FTFTT	156. TFTTT		
10. A	40. E	70. E	100. D	130. TTTTT	157. TTTTF		
11. A	41. E	71. A	101. D	131. FFFFF	158. FTFFT		
12. E	42. E	72. B	102. D	132. TTFFF	159. FFTTT		
13. E	43. D	73. E	103. C	133. TTTTF	160. TTFFT		
14. B	44. E	74. B	104. D	134. FFTTF	161. TFFTF		
15. A	45. B	75. E	105. E	135. FTTTT	162. FFTTT		
16. B	46. A	76. E	106. C	136. TFFFT	163. FFTFF		
17. E	47. B	77. B	107. D	137. TFTTT	164. FTTTT		
18. B	48. A	78. C	108. D	138. TTFTF	165. TTTTT		
19. B	49. D	79. A	109. B	139. FFTTT	166. FTTTT		
20. A	50. C	80. C	110. B	140. TTFTF	167. FFFTT		
21. C	51. D	81. A	111. C	141. TFTFF	168. TTTTT		
22. B	52. C	82. A	112. A	142. FTTTT	169. TTFTF		
23. C	53. E	83. C	113. B	143. TFTTT	170. FTTF		
24. D	54. C	84. A	114. B	144. TFTTF	171. FTTF		
25. E	55. E	85. C	115. C	145. FFFTF	172. TTTTT		
26. E	56. C	86. A	116. D	146. TFFTF	173. FTTF		
27. E	57. A	87. C	117. B	147. TTFTF	174. TTTTT		
28. D	58. E	88. C	118. C				
29. C	59. D	89. A	119. C				
30. C	60. E	90. C	120. C				
III. Slides							
181. C	182. D	183. C	184. C	185. E	186. D	187. A	188. D
		189. B	190. D	191. B	192. B	193. C	194. D
				195. A	196. B	197. A	198. A
					199. E	200. B	